

Survival of patients with intermediate stage hepatocellular carcinoma treated with superselective transarterial chemoembolization using doxorubicin-loaded DC Bead under cone-beam computed tomography control

Peter Popovic¹, Borut Stabuc², Rado Jansa², Manca Garbajs¹

¹ Clinical Institute of Radiology, University Medical Centre Ljubljana, Ljubljana, Slovenia

² Gastroenterology Department, University Medical Centre Ljubljana, Ljubljana, Slovenia

Radiol Oncol 2016; 50(4): 418-426.

Received 10 June 2015

Accepted 19 August 2015

Correspondence to: Assist. Prof. Peter Popovič, MD, PhD, Clinical Institute of Radiology University Medical Centre Ljubljana, Zaloška cesta 7, SI-1525 Ljubljana, Slovenia. Phone: +38615223415; Fax: +38615222497; E-mail: peter.popovic@gmail.com

Disclosure: Peter Popovič reports personal fees from Terumo, Philips and Bayer outside the submitted work. The other authors declare that they have no conflict of interest.

Background. The purpose of this retrospective study was to evaluate treatment response, adverse events and survival rates of patients with intermediate stage HCC treated with superselective doxorubicin-loaded DC Bead transarterial chemoembolization (DEBDOX) under cone beam computed tomography (CBCT) control.

Patients and methods. Between October 2010 and June 2012, 35 consecutive patients with intermediate stage HCC (32 male, 3 female; average age, 67.5 ± 7.8 years; 22 patients Child-Pugh class A, 8 class B, 5 without cirrhosis) were treated with DEBDOX TACE. Portal vein thrombosis was observed in 6 (17.1%) patients. DEBDOX TACE was performed by superselective catheterization of feeding vessels followed by embolization with 100-300 µm microspheres loaded with 50-100 mg of doxorubicin. In all cases, CBCT was used during chemoembolization. Tumor response rates were defined according to mRECIST criteria.

Results. Overall, 120 procedures were performed (mean, 3.2 per patients). We treated 97 lesions with an average diameter of 4.9 ± 1.9 cm. There were 32 minor and 2 (1.6%) major complications (one liver abscess and one cerebrovascular insult). After a mean follow-up of 27.7 ± 10.5 months, 94.3% of patients achieved an objective response to treatment (42.4% complete response and 57.6% partial response). Mean time to progression was 10.9 ± 5.3 months. Mean overall survival was 33.9 months (95% CI; 28.9 – 38.9 months), with 1- and 2- year survival of 97.1% and 65.7%, respectively.

Conclusions. Superselective DEBDOX TACE performed under CBCT control is a safe and effective method with high rates of tumor response and overall survival.

Key words: hepatocellular carcinoma; chemoembolization; doxorubicin; drug eluting bead; cone-beam computed tomography

Introduction

Hepatocellular carcinoma (HCC) is the fifth most common cancer and the third most common cause of cancer mortality in the world.¹ According to the Barcelona Clinic Liver Cancer (BCLC) staging sys-

tem, curative therapies (resection, transplantation, and percutaneous ablation) can improve survival in HCC patients diagnosed at an early stage and offer potential long-term curative effects.¹ About 20% of HCC patients are classified as BCLC-B, or intermediate-stage HCC.¹ Transarterial chemoembolisation

(TACE) is the standard treatment for patients with intermediate-stage HCC, but due to heterogeneity of the patient population in this stage, tumor response and survival rates are variable and scattered across the literature.²⁻⁴ Several clinical studies have confirmed the benefits of doxorubicin-loaded DC Bead (DEBDOX; drug-eluting bead doxorubicin) with respect to improved tumor response, reduced adverse events and improved survival.⁵⁻¹⁰ Furthermore, recent data shows that superselective TACE is associated with lower adverse events, higher rate of tumor response and increased survival.¹¹⁻¹³ In superselective TACE, proper identification of the tumor feeding arteries and detection of the target tumor is crucial.^{11,12,14} However, angiography frequently cannot identify HCC lesions because of their small size or decreased hypervascularity. This often results in lobar or segmental TACE of relatively large liver areas, and in turn to lower rate of tumor response and potential increase in adverse events due to high repetition of TACE. Cone-beam CT (CBCT) is a novel technique that is increasingly used during TACE for inoperable HCC.¹⁵⁻²⁰ This imaging technique uses a flat-panel detector angiographic system to produce CT-like soft-tissue images without the need to transfer the patient to a CT unit.^{15,17,19} It can be used to visualize tumor-feeding vessels and parenchymal stain during TACE, achieving detection accuracies significantly superior to standard 2D angiography.¹⁷ In this respect, the advantage of using CBCT during TACE improves the safety and effectiveness of the procedure, and has been suggested to have a benefit on local recurrence rates and overall survival during conventional TACE.^{20,21}

The purpose of this retrospective study was to evaluate treatment response, adverse events and survival rates of patients with intermediate stage HCC treated with superselective DEBDOX TACE under CBCT control.

Materials and methods

Patient selection

This single institution study included 35 patients with intermediate stage HCC that were treated with DEBDOX TACE under CBCT control between October 2010 and June 2012. Clinical examination, laboratory evaluation and CT and/or MR imaging were performed in each patient at baseline at least one month before the TACE session. The inclusion criteria for DEBDOX-TACE were intermediate stage HCC according to BCLC system. Portal vein thrombosis was not an exclusion criterion.

Written informed consent of patients was obtained before the treatments. Ethics committee approval for treatment was provided for data analysis. Ethics committee approval for treatment was not required because TACE is approved as a standard of care for intermediate stage HCC. All the procedures followed the Helsinki declaration.

TACE technique

Treatment with chemoembolization was based on the consensus of the Liver Multidisciplinary Team Meeting, held weekly at our institution. All patients underwent at least two sessions of DEBDOX TACE. After local anesthesia, a short 5 F introducer sheath (Terumo Europe N.V., Belgium) was put in place via the common femoral artery. Digital subtraction angiography (DSA) of the celiac and superior mesenteric arteries was routinely performed via a 5 F catheter (Sidewinder®, Terumo Europe N.V.) to determine vascular anatomy and variants and to assess portal flow. DSA was performed with the administration of non-ionic contrast agent iopromide 370 mg/ml (Ultravist 370®, Bayer HealthCare, Germany) through a power injector (Avanta®, Medrad, Bayer HealthCare).

The injection rate was normally 5 mL/s with a total of 20 mL injected. A 2.4 F microcatheter (Progreat®, Terumo Europe N.V.) was then superselectively positioned in the tumor feeding arteries before delivery of the DC Bead (DEBs) (DC Bead®, Terumo Europe N.V.). Prior to DEBs delivery, DSA and CBCT were performed with the administration of iopromide through a power injector to confirm complete coverage of the targeted lesion(s). DEBs with a diameter of 100-300 µm were loaded with 50 mg of doxorubicin per vial (maximum dose of 100 mg of doxorubicin). In patients with multifocal tumors, the position of the microcatheter was changed within the same session to ensure superselective DEBs delivery in each lesion (Figure 1). Delivery of the mixture was continued until a near stasis end point or the antegrade blood flow was achieved. After DEBDOX TACE, completion arteriography was performed by manual injection to minimize reflux into non-targeted areas. All patients were kept under observation for a period of 24-48 h. Second DEBDOX TACE was performed after a period of 4-6 weeks in all patients. Additional chemoembolization procedures were performed if the multifocality of the disease did not allow for complete targeting of the tumor in the first two treatment sessions (Figure 2). DEBDOX TACE treatment was repeated on demand, that is, in pa-

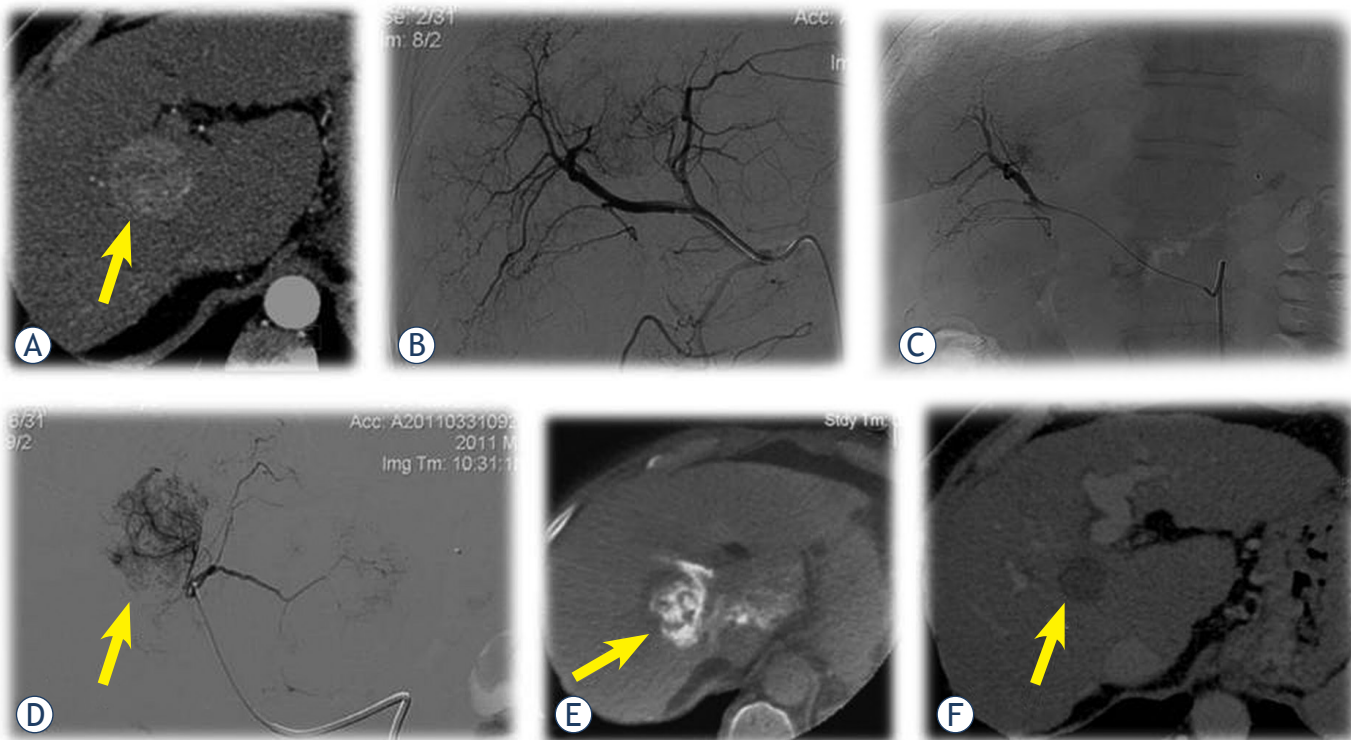


FIGURE 1. A 56-year-old female with HCC. **(A)** Contrast-enhanced CT shows tumor (arrow) between right and left liver lobe. **(B)** Initial angiography shows tumor in the liver (arrow). **(C)** Superselective contrast injection through microcatheter into segmental branches for eight liver segment confirms the tumor. **(D)** Superselective contrast injection through microcatheter into segmental branches for first liver segment also confirms the tumor (arrow). **(E)** CBCT after contrast injection through microcatheter into segmental branches for first liver segment confirms that the target lesion (arrow) is dominantly supplied from this artery and superselective DEBDOX TACE was performed from both artery. **(F)** Two months after the DEBDOX TACE, control CT shows complete devascularization of the target lesion (arrow) (complete response).

tients with residual or recurrent tumors observed by CT or MRI, according to the modified Response Evaluation Criteria in Solid Tumors (mRECIST) and in agreement with recent expert opinions.²²

Cone beam CT technique

All patients underwent C-arm single phase CBCT. Imaging was performed by using a commercially available angiography system (Allura Xper FD20®; Philips HealthCare). This system was equipped with the XperCT option, enabling C-arm CBCT acquisition and volumetric image reconstruction (Feldkamp back projection). For each CBCT scan, the area of interest was positioned in the system isocenter, and, over approximately 10 seconds, 310 projection images were acquired with the motorized C-arm, covering a 240° clockwise arc at a rotation speed of 20° per second. As the images were being acquired, the projections were transferred via fiber-optic connection to the workstation (Philips Xtravision, Rel 6.2; Dell Precision 670; Round Rock, TX/USA). The two-dimensional projection images were reconstructed by using

Feldkamp back projection into three-dimensional volumetric images with isotropic resolution of 0.98 mm for a 250 × 250 × 194-mm field of view (matrix size, 256 × 256 × 198). Typically, a 2.4-French microcatheter (Progreat®, Terumo Europe N.V.) was advanced into either a subsegmental or a segmental hepatic artery, depending on the location of the targeted tumor. CBCT was performed with the administration of non-ionic contrast agent (Ultravist 370®, Bayer HealthCare) through a power injector (Avanta®, Medrad, Bayer HealthCare). The injection rate was typically 1mL/s with a total injected volume of contrast agent 10 mL and delay time 15 seconds. The patients were instructed to be at end-expiration apnea during each CBCT acquisition. The final position of the microcatheter for delivery of the DEBs was based on the results of C-arm CBCT. This was done to superselectively deliver the bead to the tumors (Figure 3).

Follow-up

Follow-up after DEBDOX TACE included clinical evaluation, laboratory data, tumor treatment re-

sponse and serious adverse events registration. Treatment response was evaluated with contrast enhanced four-phase computed tomography (CT) or magnetic resonance (MR) imaging with hepatospecific contrast media 2 months after DEBDOX TACE according to mRECIST.²² A viable tumor was defined by contrast agent uptake in the arterial phase and washout in the portal phase and/or late phase. Radiological follow up was performed every 3 months with either contrast enhanced four-phase CT or MRI with hepatospecific contrast media. CT was performed on a 64-row multidetector CT scanner (Siemens Medical Systems®, Erlangen, Germany) and 16-row multidetector CT scanner (Siemens Medical Systems®) with a four-phase protocol (non-enhanced, arterial, portal and late venous phase), which involved the administration of 100 to 130 ml of non-ionic contrast agents (Ultravist 370®, Bayer HealthCare; Visipaque 320®, GE Healthcare) at a rate of 5 ml/s via a power injector by using a bolus tracking algorithm. Images were reconstructed at 5- and 2-mm thickness in axial and coronal planes.

MR imaging was performed on 3 T MAGNETOM Trio, A Tim Sistem scanner (Siemens Medical Systems®). All images were acquired with a phased array abdominal coil. Routine protocol included imaging by using T2 weighted fast spin echo sequences, T1 weighted fat suppressed in- and out- of phase GRE, diffusion weighted imaging and dynamic enhanced multiphasic breath-hold T1 imaging by using hepatospecific contrast agent (Primovist®, Gd-GD-EOB-DTPA, Bayer Schering Pharma AG, Germany). Images were acquired before contrast material application and during the arterial, portal, equilibrium, delayed and hepatospecific phase (after 20 minutes or more); 0.2 mM/ kg of contrast agent was injected intravenously at a rate of 1 ml/s followed by 20 ml of saline.

Tumor response, time to progression and survival assessment

Tumor response, mean time to progression and overall survival (OS) were calculated according to a follow-up time defined as the number of months from first DEBDOX TACE to 12th August 2014, last imaging control of the patient, last contact with the patient or patient's death. Treatment response was determined at every follow-up imaging control, according to mRECIST.²² Patients with complete response or partial response were classified as having an objective response to treatment.

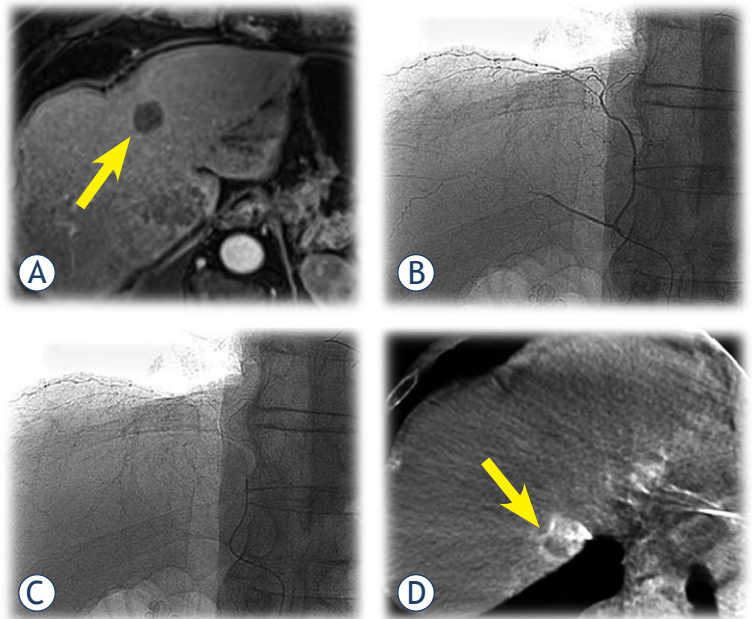


FIGURE 2. A 64-year-old male with HCC. (A) Control MR after chemoembolization shows complete response of the target lesion (arrow) in fourth segment and partial response of the target lesion in eight segment. (B) Superselective contrast injection through microcatheter into the right phrenic artery. (C) Position of microcatheter prior CBCT. (D) CBCT shows that this artery supplied the target tumor in seventh segment. Superselective DEBDOX TACE was performed.

Statistical analysis

Quantitative variables were expressed as mean \pm standard deviation and categorical as count and proportions. Survival rates and curves were determined using the Kaplan-Meier methods. Differences in the survival rate, regarding Child class were assessed using the log rank test. Last date for collection of data and calculating survival was 12th August 2014. A *p* value less than 0.05 was considered statistically significant.

Potential prognostic variables were evaluated as predictors of survival in the Cox proportional hazards model. All variables with a *p* value < 0.05 at univariate analyses were included in the multivariate analyses. All calculations were performed with statistical software (SPSS package version 19.0; SPSS Inc, Chicago, IL, USA).

Results

Patient characteristics at baseline

The baseline demographic, clinical, laboratory and tumor staging characteristics of the patients included in the analysis are summarized in Table 1. Mean

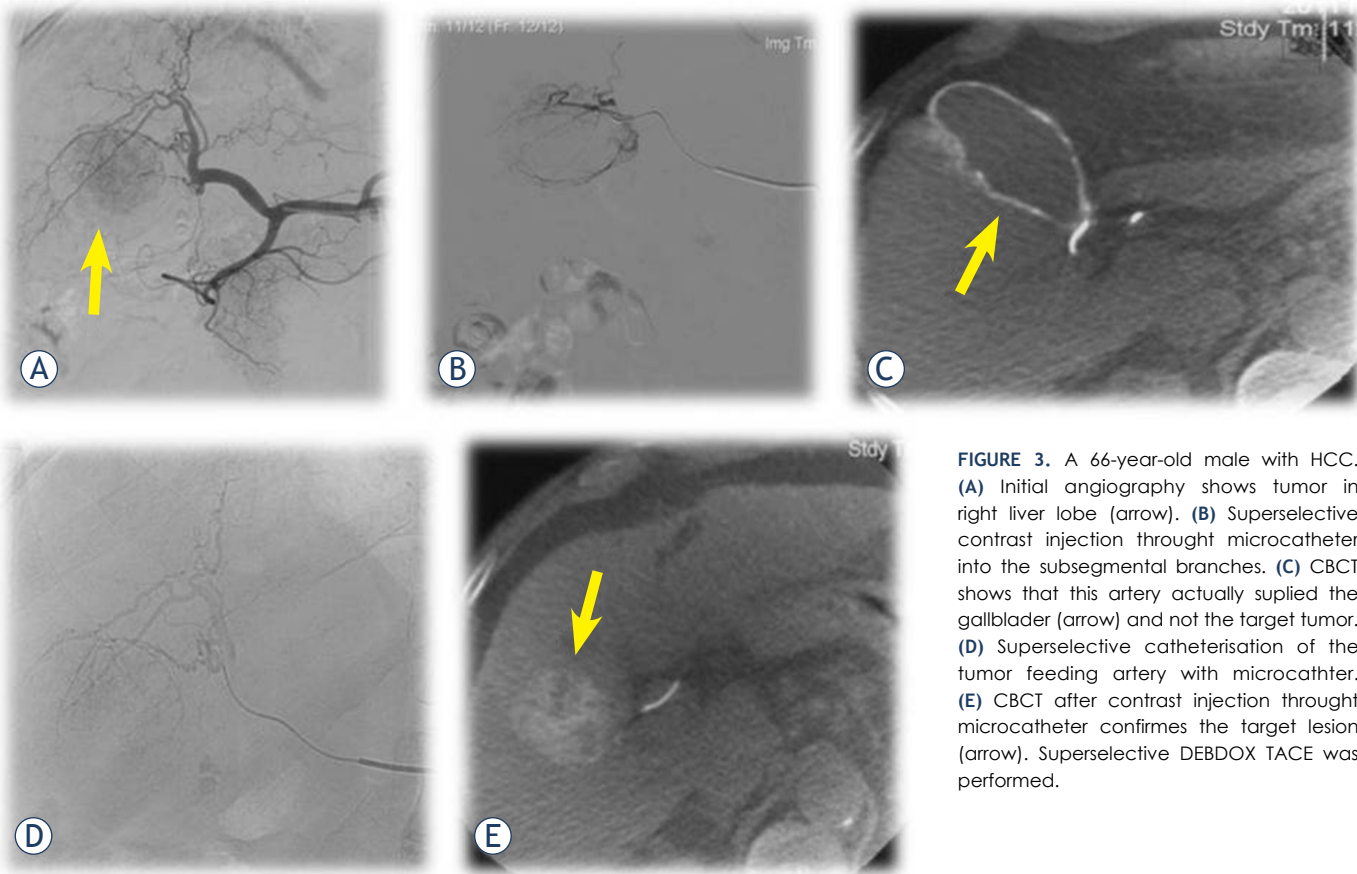


FIGURE 3. A 66-year-old male with HCC. (A) Initial angiography shows tumor in right liver lobe (arrow). (B) Superselective contrast injection through microcatheter into the subsegmental branches. (C) CBCT shows that this artery actually supplied the gallbladder (arrow) and not the target tumor. (D) Superselective catheterisation of the tumor feeding artery with microcatheter. (E) CBCT after contrast injection through microcatheter confirms the target lesion (arrow). Superselective DEBDOX TACE was performed.

patients age was 67.5 ± 7.8 years, the majority were male (32 of 35 patients). Five of 35 (11.4%) patients were not cirrhotic. The most frequent etiology of cirrhosis was ethanol (43.3%). Twenty-two patients were classified as Child-Pugh class A (73.3%) and the remaining 8 as class B (26.7%). Twenty-four of 35 (68.6%) patients had unilobar, predominantly right lobe disease. Portal vein thrombosis was observed in 6 (17.1%) patients.

Procedure and complications

Overall, 120 DEBDOX TACE procedures were performed in 35 patients. Mean number of procedures per patient was 3.2 ± 1.5 . Superselective catheterization of feeding vessels was followed by embolization with 100-300 μm microspheres loaded with 50 mg of doxorubicin. The maximum cumulative dose of doxorubicin was 100 mg. All procedures were performed under CBCT control.

Complications occurred in 34 of 120 procedures. There were two (1.6%) major complications: an ischemic cerebrovascular insult to the cerebellum and an infection of the necrotic tumor that resolved

after antibiotic treatment and resulted in prolonged hospitalization. Minor complications occurred in 32 procedures (26.6%), of which 4 procedures resulted in two complications simultaneously, which were, however, etiologically different (Table 2).

Response rate and time to progression

Thirty-three of 35 patients (94.3%) achieved an objective response after two sessions of DEBDOX TACE. Fourteen of 33 (42.4%) patients achieved complete response, while 19 (57.6%) achieved a partial response. Of the remaining two patients with no objective response, one patient had stable disease and the other had progressive disease (appearance of numerous new lesions in both liver lobes) despite continuous treatment with DEBDOX TACE. These patients were treated with sorafenib.

Twenty of 33 patients who had already achieved an objective response developed disease progression over time. Mean time to progression (TTP) was 10.9 months \pm 5.3 months (range, 5.8 – 24.8 months).

Overall survival

After a mean follow-up period of 27.7 months ± 10.5 months, 17 patients died. One patient died of acute respiratory infection with acute respiratory insufficiency, two of spontaneous bacterial peritonitis with sepsis, one of respiratory arrest, two of toxic encephalopathy, four of progression of HCC and the remaining of liver failure. Mean OS of the whole cohort was 33.9 months (95% CI: 28.9 – 38.9). 1-year survival was 97.1% and 2-year survival was 65.7%. There was no significant difference in survival between patients with cirrhosis Child A and B ($p = 0.417$). Cox regression analysis showed that none of the clinical and laboratory data were statistically significant independent risk factors for survival.

Discussion

The purpose of this retrospective study was to evaluate treatment response, adverse events and survival rates of patients with intermediate stage HCC treated with superselective DEBDOX TACE under CBCT control. By facilitating tumor targeting and super-selective therapy delivery, our results support the hypothesis that CBCT plays a key role in achieving satisfactory tumor response and OS.^{20,21}

TACE is the most widely used loco-regional therapy for patients with intermediate stage HCC. The number of treatment sessions depends on the response of the tumor and whether serious side effects are seen.^{3-5,7} The overall response rate for this treatment is about 50%, with the lowest reported around 15% and the highest around 85.6%.^{2-5,16} In a prospective study of 67 consecutive patients (122 nodules, all < 5 cm), Golfieri *et al.* showed that, when compared with lobar conventional TACE (cTACE), selective/superselective cTACE was associated with higher mean levels of necrosis (75.1% versus 52.8%; $p = 0.002$) and a higher rate of complete necrosis (53.8% versus 29.8%, $p = 0.013$).¹¹ These findings suggest that selective/superselective cTACE may determine a higher rate of tumor necrosis than lobar TACE. With improved treatment efficacy and tolerance, DEBDOX TACE represents a major advancement in treatment of intermediate stage HCC.^{2,6,9,10,23} In a recent prospective, randomized phase II study comparing cTACE with DEBDOX TACE, the DEBDOX TACE group showed a trend for a higher objective response rate than the cTACE group (51.6% versus 43.5%, respectively), together

TABLE 1. Baseline demographic, clinical, laboratory and tumor staging characteristics of patients

Characteristic	Value
Age, [years]	67.5 ± 7.8
Gender (M/F), n [%]	32/3 [91.4/8.6]
Cirrhosis (yes/no), n [%]	30/5 [85.7 /14.3]
Etiology of cirrhosis, n [%]:	
Ethanol	13 [43.3]
HBV	4 [13.3]
HCV	4 [13.3]
other	9 [29.9]
Albumin [g/l]	38.4 ± 4.6
INR	1.2 ± 0.2
Total bilirubin [μmol/l]	25.6 ± 17.4
Child-Pugh score (points)	6.0 ± 0.7
Child-Pugh score (classes), n [%]:	
A	22 [73.3]
B	8 [26.7]
Creatinine [μmol/l]	81.7 ± 23.4
ASAT [μkat/l]	1.1 ± 0.7
ALAT [μkat/l]	0.8 ± 0.6
γGT [μkat/l]	2.3 ± 1.6
αFP [kIE/l]	152.5 ± 310.2
Portal vein thrombosis (yes/no), n [%]	6/29 [17.1/82.9]
Bilobar disease, n [%]	11 [31.4]
Unilobar disease, n [%]:	
right lobe, n [%]	24 [68.6]
left lobe, n [%]	20 [83.3]
Overall number of nodules, n	97
Number of nodules per pt, n	2.8 ± 2.2
Maximum diameter of HCC nodule per pt. [cm]	4.7 ± 1.9

HBV = hepatitis B virus, HCV = hepatitis C virus; INR = international normalised ratio; ASAT = aspartate aminotransferase; ALAT = alanine aminotransferase; γGT = gamma glutamyl transpeptidase; αFP = alpha-feto protein; pt = patient. Quantitative variables expressed as mean ± standard deviation.

with better tolerability.^{8,24} In another prospective, randomized study, DEBDOX TACE resulted in a better objective response than bland embolization with non-loaded bead (73.1% versus 55.9%, respectively).¹⁰ Similarly, Boatta and colleagues showed a 72% objective response rate in 154 patients treated with DEBDOX TACE.²⁴ In a study by Suk *et al.*, where CBCT after DEBDOX TACE was used to predict short-term tumor response according to mRECIST, objective response was achieved in 85.6% of patients (complete response 63.8%, partial response 21.8%), and objective response rates at one month after CBCT-guided TACE was also reported in a study by Loffroy *et al.* in 78% of patients (complete response 46.3%, partial response 26.8%).^{2,16} In a retrospective study of 116 consecutive patients Georgiades *et al.* showed that delivery

of two treatment sessions also lead to higher tumor response.²⁵

Our results show a very high percentage (91.9%) of objective response defined according to mRECIST. The most plausible reasons for high objective response rate in our study were the routine utilization of CBCT control to guide superselective DEBDOX TACE in all patients and the delivery of at least two treatment sessions for all lesions.

TACE is also associated with OS benefits, reported in a meta-analysis of randomized controlled trials.^{3,26} Reported 1-, 2- and 3-year survival rates ranged from 24% to 90%, 59% to 81% and 29% to 47%, respectively.^{3,13,21,25,27} However, most of these studies assessed cTACE.^{3,4,6} Studies reporting on survival of patients treated with DEBDOX TACE are scarce. A retrospective case-control study from a single academic institution in the United States demonstrated a survival benefit for patients undergoing DEBDOX TACE versus cTACE.²³ One-year and 2-year survival were superior with DEBDOX TACE.²⁸

In a recent study from Burrel *et al.* that analyzed strictly selected patients with intermediate stage HCC treated with DEBDOX TACE in a highly specialized center, reported 1- and 3-year OS rates equal to 89.9% and 66.3%, respectively. Median survival time in this study was 48.6 months.⁶ The overall favourable efficacy of DEBDOX TACE was further corroborated by a recent international, long-term (5 years of follow-up) study, where OS at 5 years was 22.5% and the mean OS was 43.8 months.²⁹ To our knowledge there is only one study determining survival of HCC patients treated with TACE under CBCT control. This study showed that patients receiving CBCT-assisted cTACE had significantly higher OS rates than those receiving cTACE with angiography alone. OS rates of patients who underwent chemoembolization under CBCT assistance were 94%, 81% and 71% at 1, 2, and 3 years, respectively.²¹ OS rates in our study were 97% at 1 year, 66% at 2 years, with an average survival of 33.9 months. In particular, 1-year survival rate of our patients was higher than in most other studies reported in the literature, while 2-year survival was only marginally lower than the results reported by Iwazawa *et al.*, where cTACE was also performed under CBCT control (2-year survival, 81%).²¹ The high 1-year OS reported in our study may be related to the high objective response rates achievable with DEBDOX TACE, supported by the fact that objective response to treatment correlates with prolonged OS.³⁰ In addition, the most com-

TABLE 2. Number and type of minor complications after DEBDOX TACE.

Type of complication	No. of complications
Post-embolization syndrome*	23
Rise in blood pressure	4
Gastric erosions or ulcers	2
Chest pain	2
Hematoma at puncture site	1

*Post-embolization syndrome was defined as elevated body temperature, pain in the abdomen, nausea and/or vomiting, leukocytosis and elevated liver enzymes.

mon reason for death in our study was not related to progression of HCC but rather to liver cirrhosis, which may explain the significant drop in 2-year survival.

TACE-associated adverse events, although usually transient and manageable, occur in a significant proportion (35 – 100%) of patients, and may include post-embolization syndrome (comprising of fever, abdominal pain and a moderate degree of ileus), relevant liver function deterioration, ascites and gastrointestinal bleeding.¹¹ Our analysis shows that DEBDOX TACE under CBCT control is a safe treatment method. The majority of complications were minor, either self limited or managed conservatively. One of the two major complications, infection of tumor necrosis, was due to the fact that necrotic tissue is an optimal culture medium for bacteria.⁶ The other major complication was a cerebrovascular insult. This was likely due to the reflux of the contrast and DEB particles mixture from an extrahepatic feeding artery (mammary artery) into the basilar artery that resulted in ischemic injury to the cerebellum. To our knowledge, 12 other cases with 25% mortality are reported in the literature.³¹ Our patient, however, died of liver failure 5 months after the procedure. Thus, no treatment-related deaths were reported.

We speculate that the utilization of intraprocedural CBCT and delivery of at least two treatment sessions for all lesions contributed to the high response rates, low occurrence of adverse events and good OS reported in our study. This imaging technique provides cross sectional, soft-tissue, CT-like images without the need to move the patient to a CT room and offers many advantages over classic 2D angiography alone.^{15,17,19,32} First, CBCT detection accuracy of HCC lesions is equivalent to multidetector CT and MRI and superior to 2D

angiography.^{15,17,19} Second, it is the most accurate imaging technique to identify tumor-feeding arteries.¹⁴ Third, selective CBCT during hepatic angiography may be used to rule out non-target embolization to non-tumor feeding extrahepatic arteries and ensure that the selected branch supplies the tumor safety margin.^{17,18,33,34} In this respect, CBCT can also help with catheter placement when synchronous non-tumor and tumor enhancement are seen and can distinguish between tumor and non-tumor staining, most frequently occurring with feeding from the inferior phrenic artery.¹⁸ Finally, effective radiation doses for CBCT have been reported to be lower than with conventional.^{2,18}

CBCT also has some limitations. Its contrast resolution is lower than that of conventional CT, thus providing less differentiation between HCCs and surrounding liver parenchyma.^{18,19} Furthermore, the detection of HCCs under diaphragm may be impaired by motion artefacts, while streak artefacts from the catheter and contrast material may also degrade image quality.^{15,18,19} The field of view of CBCT is smaller than that of conventional CT and liver truncation may occur.¹⁸ Finally, the acquisition of CBCT images requires additional contrast administration. This can be balanced with the use of CBCT guidance software to guide micro-catheter positioning to the targeted arteries, which may in turn help to reduce both radiation exposure and contrast administration.¹⁷

There are some limitations in our study. First, this study was a retrospective analysis and lacks a control group, thus failing to provide robust data of a prospective randomized controlled trial. In particular, we decided to avoid randomization between superselective DEBDOX TACE under CBCT and superselective DEBDOX TACE without CBCT, because of the anticipated clinical advantages of CBCT. Second, our small sample size may have introduced a selection bias. The BCLC B stage includes a heterogenous population of HCC patients and there is lack of a standard treatment methodology and patient selection criteria for TACE.²⁵ Therefore, our patient selection criteria were strict in order to achieve the best outcome. Third, histopathologic correlation with CT or MR imaging regarding tumor necrosis after treatment with DEBDOX TACE was not performed since previous reports already showed good correlation between the percentage of tumor necrosis obtained at histopathologic examination and the tumor enhancement assessed with imaging.^{11,16}

In conclusion, superselective DEBDOX TACE performed under CBCT control is a safe and effective

method with high tumor response and survival rates. Further prospective studies with a larger number of patients are required to elucidate the incremental benefit when compared to conventional techniques.

References

1. El-Serag HB, Rudolph KL. Hepatocellular carcinoma: epidemiology and molecular carcinogenesis. *Gastroenterology* 2007; **32**: 2557-76.
2. Suk Oh J, Jong Chun H, Gil Choi B, Gyu Lee H. Transarterial chemoembolization with drug-eluting bead in hepatocellular carcinoma: usefulness of contrast saturation features on cone-beam computed tomography imaging for predicting short-term tumor response. *J Vasc Interv Radiol* 2013; **24**: 483-9.
3. Llovet JM, Bruix J. Systematic review of randomized trials for unresectable hepatocellular carcinoma: Chemoembolization improves survival. *Hepatology* 2003; **37**: 429-42.
4. Lo CM, Ngan H, Tso WK, Liu CL, Lam CM, Poon RT, et al. Randomized controlled trial of transarterial lipiodol chemoembolization for unresectable hepatocellular carcinoma. *Hepatology* 2002; **35**: 1164-71.
5. European Association For The Study Of The Liver and European Organisation For Research And Treatment Of Cancer. EASL-EORTC clinical practice guidelines: management of hepatocellular carcinoma. *J Hepatol* 2012; **56**: 908-43.
6. Burrel M, Reig M, Forner A, Barrufet M, de Lope CR, Tremosini S, et al. Survival of patients with hepatocellular carcinoma treated by transarterial chemoembolisation (TACE) using Drug Eluting Beads. Implications for clinical practice and trial design. *J Hepatol* 2012; **56**: 1330-5.
7. Kim GM, Kim HC, Chung JW, Lee IJ, Kim HM, Jae HJ, et al. Chemoembolization for hepatocellular carcinoma supplied exclusively by the hepatic falciform artery. *Cardiovasc Intervent Radiol* 2012; **35**: 845-51.
8. Lammer J, Malagari K, Vogl T, Pilleul F, Denys A, Watkinson A, et al. Prospective randomized study of doxorubicin-eluting-bead embolization in the treatment of hepatocellular carcinoma: results of the PRECISION V study. *Cardiovasc Intervent Radiol* 2010; **33**: 41-52.
9. Lencioni R, Petruzzi P, Crocetti L. Chemoembolization of Hepatocellular Carcinoma. *Semin Intervent Radiol* 2013; **30**: 3-11.
10. Malagari K, Pomoni M, Kelekis A, Pomoni A, Dourakis S, Spyridopoulos T, et al. Prospective randomized comparison of chemoembolization with doxorubicin-eluting beads and bland embolization with BeadBlock for hepatocellular carcinoma. *Cardiovasc Intervent Radiol* 2010; **33**: 541-51.
11. Golfieri R, Cappelli A, Cucchetti A, Piscaglia F, Carpenzano M, Peri E, et al. Efficacy of selective transarterial chemoembolization in inducing tumor necrosis in small (< 5 cm) hepatocellular carcinomas. *Hepatology* 2011; **53**: 1580-9.
12. Jin B, Wang D, Lewandowski RJ, Riaz A, Ryu RK, Sato KT, et al. Chemoembolization endpoints: effect on survival among patients with hepatocellular carcinoma. *Am J Roentgenol* 2011; **196**: 919-28.
13. Takayasu K. Superselective transarterial chemoembolization for hepatocellular carcinoma: recent progression and perspective. *Oncology* 2011; **81(Suppl 1)**: 105-10.
14. Iwazawa J, Ohue S, Mitani T, Abe H, Hashimoto N, Hamuro M, et al. Identifying feeding arteries during TACE of hepatic tumors: comparison of C-arm CT and digital subtraction angiography. *AJR Am J Roentgenol* 2009; **192**: 1057-63.
15. Higashihara H, Osuga K, Onishi H, Nakamoto A, Tsuboyama T, Maeda N, et al. Diagnostic accuracy of C-arm CT during selective transcatheter angiography for hepatocellular carcinoma: comparison with intravenous contrast-enhanced, biphasic, dynamic MDCT. *Eur Radiol* 2012; **22**: 872-9.
16. Loffroy R, Lin M, Yenokyan G, Rao PP, Bhagat N, Noordhoek N, et al. Intra-procedural C-arm dual-phase cone-beam CT: can it be used to predict short-term response to TACE with drug-eluting beads in patients with hepatocellular carcinoma? *Radiology* 2013; **266**: 636-48.

17. Floridi C, Radaelli A, Abi-Jaoudeh N, et al. C-arm cone-beam computed tomography in interventional oncology: technical aspects and clinical applications. *Radiol Med* 2014; **119**: 521-32.
18. Tacher V, Radaelli A, Lin M, Geschwind JF. How I Do It: Cone-Beam CT during Transarterial Chemoembolization for Liver Cancer. *Radiology* 2015; **274**: 320-34.
19. Miyayama S, Yamashiro M, Okuda M, Yoshie Y, Sugimori N, Igarashi S, et al. Usefulness of cone-beam computed tomography during ultraselective transcatheter arterial chemoembolization for small hepatocellular carcinomas that cannot be demonstrated on angiography. *Cardiovasc Intervent Radiol* 2009; **32**: 255-64.
20. Miyayama S, Yamashiro M, Hashimoto M, Hashimoto N, Ikuno M, Okumura K, et al. Comparison of local control in transcatheter arterial chemoembolization of hepatocellular carcinoma \leq 6 cm with or without intraprocedural monitoring of the embolized area using cone-beam computed tomography. *Cardiovasc Intervent Radiol* 2014; **37**: 388-95.
21. Iwazawa J, Ohue S, Hashimoto N, Muramoto O, Mitani T. Survival after C-arm CT-assisted chemoembolization of unresectable hepatocellular carcinoma. *Eur J Radiol* 2012; **81**: 3985-92.
22. Lencioni R, Llovet JM. Modified RECIST (mRECIST) assessment for hepatocellular carcinoma. *Semin Liver Dis* 2010; **30**: 52-60.
23. Dhanasekaran R, Kooby DA, Staley CA, Kauh JS, Khanna V, Kim HS. Comparison of conventional transarterial chemoembolization (TACE) and chemoembolization with doxorubicin drug eluting beads (DEB) for unresectable hepatocellular carcinoma (HCC). *J Surg Oncol* 2010; **101**: 476-80.
24. Boatta E, Corona M, Cannavale A, Fanelli F, Cirelli C, de Medici L. Endovascular treatment of hepatocellular carcinoma with drug eluting microparticles (DC-Beads): CT evaluation of response to the treatment. *Indian J Radiol Imaging* 2013; **23**: 126-33.
25. Georgiades C, Geschwind JF, Harrison N, Hines-Peralta A, Liapi E, Hong K, et al. Lack of response after initial chemoembolization for hepatocellular carcinoma: does it predict failure of subsequent treatment? *Radiology* 2012; **265**: 115-23.
26. Lencioni R, Chen XP, Dagher L, Venook AP. Treatment of intermediate/advanced hepatocellular carcinoma in the clinic: how can outcomes be improved? *Oncologist* 2010; **4**(Suppl 15): 42-52.
27. Cabibbo G, Genco C, Di Marco V, Barbara M, Enea M, Parisi P, et al. Predicting survival in patients with hepatocellular carcinoma treated by transarterial chemoembolisation. *Aliment Pharmacol Ther* 2011; **34**: 196-204.
28. Huang K, Zhou Q, Wang R, Cheng D, Ma Y. Doxorubicin-eluting beads versus conventional transarterial chemoembolization for the treatment of hepatocellular carcinoma. *J Gastroenterol Hepatol* 2014; **29**: 920-5.
29. Malagari K, Pomoni M, Moschouris H, Bouma E, Koskinas J, Stefanidou A, et al. Chemoembolization with doxorubicin-eluting beads for unresectable hepatocellular carcinoma: five-year survival analysis. *Cardiovasc Intervent Radiol* 2012; **35**: 1119-28.
30. Kim BK, Kim SU, Kim KA, Chung YE, Kim MJ, Park MS, et al. Complete response at first chemoembolization is still the most robust predictor for favorable outcome in hepatocellular carcinoma. *J Hepatol* 2015; **62**: 1304-10.
31. Zach V, Rapaport B, Yoo JY, Goldfeder L, Weinberger J. Multiple ischemic strokes after transcatheter arterial chemoembolization for hepatocellular carcinoma with a radiographic and pathological correlate. *J Stroke Cerebrovasc Dis* 2012; **21**: 217-24.
32. Loffroy R, Favelier S, Cherblanc V, Estivalet L. C-arm dual-phase cone-beam CT: a revolutionary real-time imaging modality to assess drug-eluting beads TACE success in liver cancer patients. *Quant Imaging Med Surg* 2013; **3**: 196-9.
33. Kim HC, Chung JW, Lee W, Jae HJ, Park JH. Recognizing extrahepatic collateral vessels that supply hepatocellular carcinoma to avoid complications of transcatheter arterial chemoembolization. *Radiographics* 2005; **1**(Suppl 25): 25-39.
34. Miyayama S, Matsui O, Taki K, Minami T, Ryu Y, Ito C, et al. Extrahepatic blood supply to hepatocellular carcinoma: angiographic demonstration and transcatheter arterial chemoembolization. *Cardiovasc Intervent Radiol* 2006; **29**: 39-48.