

Anatomic variations of the pancreatic duct and their relevance with the Cambridge classification system: MRCP findings of 1158 consecutive patients

Zehra Hilal Adibelli¹, Mustafa Adatepe², Cetin Imamoglu¹, Ozgur Sipahi Esen¹, Nazif Erkan³, Mehmet Yildirim³

¹ Department of Radiology, Bozyaka Training and Research Hospital, Izmir, Turkey

² Department of Radiology, Urfa Balıklıgöl State Hospital, Urfa, Turkey

³ Department of Surgery, Bozyaka Training and Research Hospital, Izmir, Turkey

Radiol Oncol 2016; 50(4): 370-377.

Received 9 May 2016
Accepted 6 June 2016

Correspondence to: Assoc. Prof. Zehra Hilal Adibelli, M.D., Department of Radiology, Bozyaka Training and Research Hospital, Izmir, Turkey. Phone: +90 532 7970472; E-mail: adibellizehra@gmail.com, adibellizh@myinet.com

Disclosure: No potential conflicts of interest were disclosed.

Background. The study was conducted to evaluate the frequencies of the anatomic variations and the gender distributions of these variations of the pancreatic duct and their relevance with the Cambridge classification system as morphological sign of chronic pancreatitis using magnetic resonance cholangiopancreatography (MRCP).

Patients and methods. We retrospectively reviewed 1312 consecutive patients who referred to our department for MRCP between January 2013 and August 2015. We excluded 154 patients from the study because of less than optimal results due to imaging limitations or a history of surgery on pancreas. Finally a total of 1158 patients were included in the study.

Results. Among the 1158 patients included in the study, 54 (4.6%) patients showed *pancreas divisum*, 13 patients (1.2%) were defined as *ansa pancreatica*. When we evaluated the course of the pancreatic duct, we found the prevalence 62.5% for descending, 30% for sigmoid, 5.5% for vertical and 2% for loop. The most commonly observed pancreatic duct configuration was Type 3 in 528 patients (45.6%) where 521 patients (45%) had Type 1 configuration.

Conclusions. Vertical course ($p = 0.004$) and Type 2 ($p = 0.03$) configuration of pancreatic duct were more frequent in females than males. There were no statistically significant differences between the gender for the other pancreatic duct variations such as *pancreas divisum*, *ansa pancreatica* and course types other than vertical course ($p > 0.05$ for all). Variants of *pancreas divisum* and normal pancreatic duct variants were not associated with morphologic findings of chronic pancreatitis by using the Cambridge classification system. The *ansa pancreatica* is a rare type of anatomical variation of the pancreatic duct, which might be considered as a predisposing factor to the onset of idiopathic pancreatitis.

Key words: pancreas divisum; pancreatic duct variants; magnetic resonance imaging; magnetic resonance cholangiopancreatography

Introduction

Pancreatitis can be fatal and remains a serious disease. It occurs in two forms as acute and chronic with different clinic, morphological and histological features.¹ Chronic pancreatitis is characterized

by progressive inflammation, fibrosis of pancreas leading to irreversible structural changes.¹ Excessive alcohol consumption, cigarette smoking, autoimmunity, high protein diet, heredity factor and also several morphological anomalies of the pancreaticobiliary ductal system like abnormal

pancreaticobiliary junction and *pancreas divisum* are thought as causes of chronic pancreatitis.^{1,2} Except *pancreas divisum*, pancreatic duct variations are not well evaluated.³ To define risk factors for the appearance of chronic pancreatitis and to understand the pathophysiology including further underlying causes of chronic pancreatitis are important.

Normal variants and congenital anomalies of the pancreas and the pancreatic duct may not be detected in asymptomatic patients until maturity and even when they are detected, it is often incidental.^{4,5} The variations and anomalies of the pancreatic and the biliary ductal system are commonly experienced during radiologic examinations.⁶ Endoscopic retrograde cholangiopancreatography (ERCP) is considered as the gold standard for the evaluation of pancreatic ductal system and chronic pancreatitis because of its superior spatial resolution and its ability to show main duct and side branch abnormalities with severity assessed using the Cambridge classification. The Cambridge classification divides chronic pancreatitis to five severity groups according to morphologic changes of the main pancreatic duct and its side branches from normal or equivocal to mild, moderate, severe.⁷ Magnetic resonance cholangiopancreatography (MRCP) is becoming more commonly used in the noninvasive evaluation of the pancreatic and the biliary ducts.¹⁻⁸ MRCP detects pancreatic ductal system and also these variations with similar accuracy as the invasive technique of endoscopic retrograde cholangiopancreatography (ERCP).^{3,9} In MRCP, heavily T2 weighted sequences are used to image fluid filled structures without using contrast agent. MRCP has certain advantages over ERCP, it is safer (no exposure to ionizing radiation, no using contrast agent, no premedication), it can be used for staging malignancy and it does not carry the risk of developing complications, can be applied during acute attacks of pancreatitis and cholangitis, gives the chance to view the extraductal structures by using the conventional T1-T2-weighted images.¹⁰ Also, the Cambridge classification has been modified for the MRCP technique.¹¹⁻¹³ The using of MRCP in adult patients with persistent and unexplained signs and symptoms such as abdominal pain, nausea and vomiting resulting from chronic pancreatitis or gastric outlet obstruction gives an option to look for a developmental anomaly of pancreas and pancreatic duct. It is important to recognize of these anomalies because they may be a surgically correctable cause of recurrent pancreatitis or the cause of gastric outlet obstruction. Awareness of these anomalies may provide useful

information in surgical planning and prevent of inadvertent ductal injury.

Pancreas divisum is the most frequent anatomical variation of pancreatic ductal patterns.²⁻⁶ While the frequency of classical *pancreas divisum* has been evaluated to be between 5 and 10% in large series², the frequency of other anatomic variations of pancreatic duct, sub-type of *pancreas divisum* and the gender distributions of these variations of the pancreatic duct and their relevance with the Cambridge classification system are unknown. This study was conducted in order to evaluate anatomic variations and developmental anomalies of pancreatic duct; including the variations of the course and the configuration of the pancreatic duct, anomalous pancreaticobiliary ductal junction, subtypes of *pancreas divisum* and the gender distributions of these variations of the pancreatic duct. We also aimed to show their relevance with the Cambridge classification system which we used for scoring ductal changes as morphological sign of chronic pancreatitis with the largest sample size in the literature best of our knowledge. This sample consists of a group of patients who underwent MRCP for various reasons in one center during a certain time interval.

Patients and methods

Patient population

We retrospectively reviewed MRCPs obtained at our radiology department between January 1, 2013 and August 30, 2015 after obtaining the approval of the ethical board. A total of 1312 cases were examined, 154 cases with less than optimal results due to imaging limitations, failure to visualize the main pancreatic duct and with a history of surgery on pancreas, were excluded from the study. A total of 1158 cases were included in the study. The study was performed according the Helsinki Declaration and the Institutional Review Board Committee was approved it.

Imaging

We performed the MRI examinations of the patients in our radiology department using a 1.5 T MR device (Philips Achiva, Philips Medical System, the Netherlands). Patients were informed about the MRCP imaging and following a 6-hour fasting period and after any metal items or objects on the patients which may produce artifacts were removed. Oral or intravenous contrast material was not used during the investigations. But

TABLE 1. MRI sequence parameters

	TR	TE	MATRIX	N OF SLICE	SLICE THICKNESS	FOV	NSA	TSE-TFE FACTOR	SLAB THICK.
T2 W Images (Ax and Coronal)	962ms	100 ms	256x256	24	6 mm	350-400 mm	2	158	-
GRE Balanced TFE (Ax and Coronal)	4 ms	1.24 ms	156x213	24	7 mm	300-400 mm	2	219	-
3D-TSE T2 W respiratory-triggered	1466 ms	650 ms	256x256	1	0.8 mm	250-300 mm	1	105	40 mm

Ax = axial; ETL = echo train length; GRE = gradient-recalled echo; N = number; NSA = number of signal acquired; TE = echo time; TFE = turbo field echo; TR = repetition time; TSE = turbo spin echo; W = weighted

in some cases, we also performed abdominal MRI with intravenous contrast material at the time of MRCP or sometimes after MRCP when we found some lesions which need additional information.

In all patients, MR examinations were made including coronal and axial T2-weighted turbo spin echo (TSE) images (repetition time [TR]: 962 ms, echo time [TE]: 100 ms, Matrix: 256 x 256, number of slice: 24, slice thickness: 6 mm, field of view [FOV]: 350–400 mm, SENSE factor: 4, number of signal acquired [NSA]: 2), coronal and axial gradient-recalled echo (GRE) balanced turbo field echo (TFE) images (TR: 4 ms, TE: 1.24 ms, Matrix: 156 x 213, number of slice: 24, slice thickness: 7 mm, FOV: 300–400 mm, Flip angle: 80, NSA: 2). The choledochus was located in the images in the axial-coronal plane, then respiratory-triggered high-resolution with SENSE 3D-TSE T2-weighted (TR: 1466 ms, TE: 650 ms, echo train length [ETL]: 128, matrix: 256 x 256, NSA: 1, slice thickness: 0.8 mm, FOV: 250–300 mm); para-coronal MRCP source and maximum intensity projection (MIP) reformatted images were obtained. MRCP is performed with heavily T2-weighted sequences with a torso phased-array coil (Table 1).

Evaluation of the images

Two radiologists with experience in abdominal imaging of 15 years (Z.H.A.) and 1 year (M.A.) reviewed the MRCP images retrieved from Picture Archiving and Communication System (PACS) of our hospital. Discordant interpretations were subsequently resolved by consensus of the 2 radiologists.

The course of the pancreatic duct was evaluated as descending (Figure 1), sigmoid (Figure 2), vertical (Figure 3), and loop (Figure 4) shaped courses.^{5,14}

The ductal configuration was evaluated as Type 1–Type 5 (Figure 5). At Type 1, there was a bifid configuration with dominant duct of Wirsung, at Type 2, there was a dominant duct of Santorini without *divisum*, at Type 3, Wirsung duct was seen

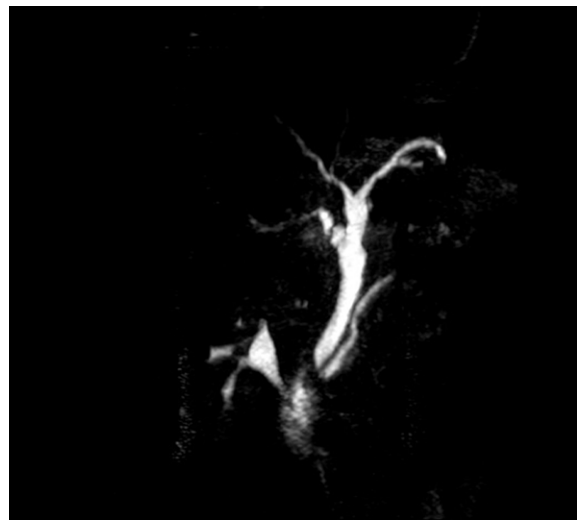


FIGURE 1. Descending course of pancreatic duct in 60 year of woman who had cholecystectomy. There is a Type 3b variation (the right posterior duct drained into the main hepatic duct) at the level of bifurcation of the biliary ducts and mild forms of renal pelvis dilatation.

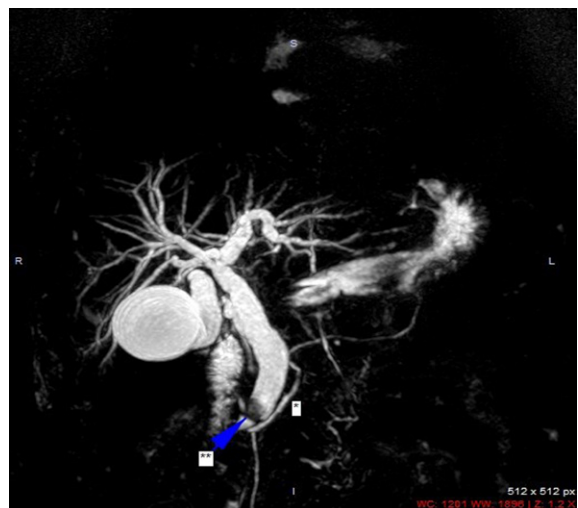


FIGURE 2. Sigmoid course of pancreatic duct in 49 year-old woman with and trifurcation at the level of bifurcation of the biliary ducts (*); Sigmoid course of the pancreatic duct, (**); choledocholithiasis.

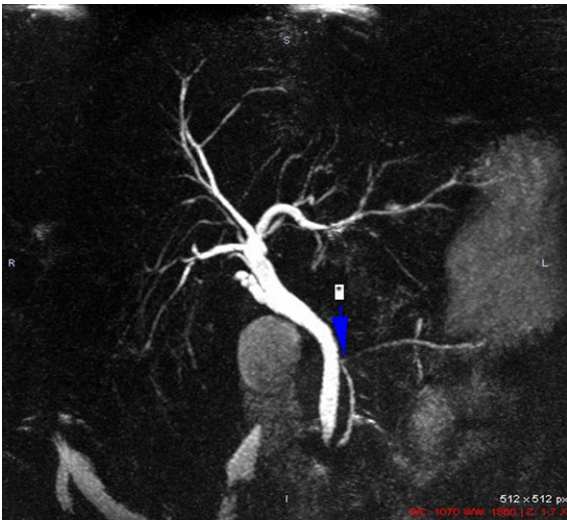

FIGURE 3. Vertical course (*) of pancreatic duct in 55 year-old woman who had cholecystectomy.

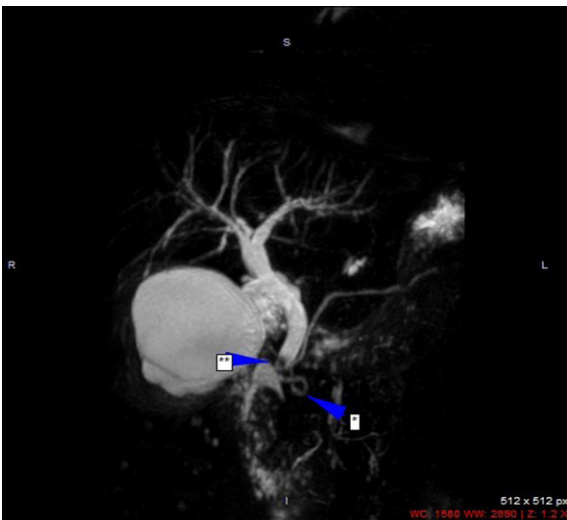


FIGURE 4. Loop course (*) of pancreatic duct in 38 year-old woman with choledocholithiasis (**).

with absent duct of Santorini. We mentioned *pancreas divisum* as Type 4 and ‘ansa pancreatica’ as Type 5, where the duct of Santorini formed an in-

ferior loop and connected with a side branch of the duct of Wirsung in the *uncinate* process.^{5,6,14}

Three variants of *pancreas divisum* were evaluated as; in subtype 1 or classical *divisum*, there was total failure of fusion; in subtype 2, there was only dominant dorsal drainage with the absence of the duct of Wirsung; in subtype 3 or incomplete *divisum*, a small communicating branch was present.⁵

Anomalous pancreaticobiliary ductal junction was described the abnormal junction of the common biliary duct (CBD) and the pancreatic duct outside the duodenal wall forming a long common channel (> 15 mm).^{5,6}

We used the Cambridge classification system which has been modified for the MRCP technique: Cambridge 1 (normal pancreas): pancreatic ducts are normal; Cambridge 2 (*equivocal pancreas*): 1–2 side branches and main duct 2–4 mm; Cambridge 3 (mild disease): ≥ 3 side branches and main duct 2–4 mm; Cambridge 4 (moderate disease): ≥ 3 side branches and main duct > 4 mm; Cambridge 5 (marked disease): additional feature include a large cavity, obstruction, a filling defect, severe dilatation or irregularity^{11–13} MRCP was called normal when main duct calibers at the pancreatic head, body, and tail were less than 3 mm, 2.5 mm, and 1.5 mm, respectively, and when no pancreatic duct side branch ectasia was identified. We could not differentiate Cambridge 2 and 3 from each other where main pancreatic duct was normal by using MRCP; we evaluated Cambridge 2 and 3 together.

Statistical analysis

Fisher’s exact test and χ square test were used as statistical methods in the study. When samples were small and the assumptions for the χ square were violated, the Fisher’s exact test was used. For example, in a 2 × 2 Table when expected cell counts were less than 5, or any were less than 1 even, Yates correction does not work and Fisher exact test was used instead of χ square test. Statistical significance was

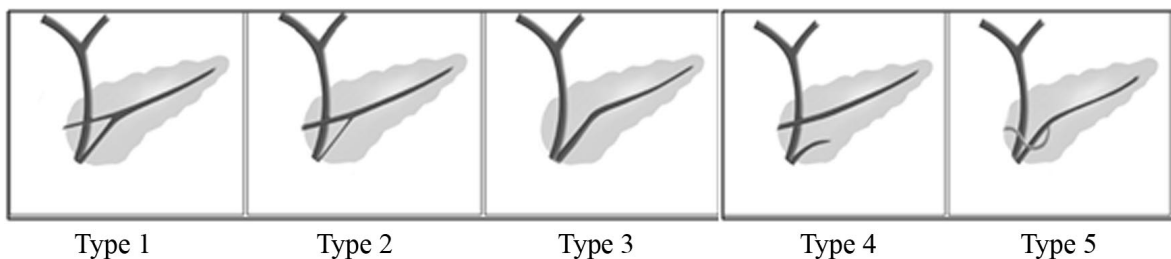


FIGURE 5. Variations in the configuration of the pancreas duct. Type 1: Bifid configuration with dominant duct of Wirsung, Type 2: Bifid configuration with dominant duct of Santorini without divisum, Type 3: Rudimentary non-draining duct of Santorini, Type 4: *Pancreas divisum*, Type 5: *Ansa pancreatica*.

TABLE 2. The distribution of the course types of main pancreatic duct

	Number of variations n (%)	Male n (%)	Female n (%)
Descending type	724 (62.5)	321 (65.5)	403 (60)
Sigmoid type	343 (30)	134 (27.5)	199 (30)
Vertical type	68 (5.5)	17 (5.4)	51 (7.8)
Loop type	23 (2)	8 (1.6)	15 (2.2)
Total	1158	490	668

TABLE 3. The distribution of ductal configuration types of main pancreatic duct

Variation in configuration	Number of Variations, n (%)	Male, n (%)	Female, n (%)
Type 1	521 (45)	233 (47.5)	288 (43.1)
Type 2	42 (3.6)	11 (2.3)	31 (4.6)
Type 3	528 (45.6)	220 (44.9)	308 (46.1)
Type 4	54 (4.6)	19 (3.9)	35 (5.3)
Type 5	13 (1.2)	7 (1.4)	6 (0.9)
Total	1158	490	668

Type 1 = a bifid configuration with a dominant duct of Wirsung; Type 2 = a bifid configuration with dominant duct of Santorini without *divisum*; Type 3 = Wirsung duct is seen with absent duct of Santorini or rudiment duct of Santorini without communication with Wirsung; Type 4 = *pancreas divisum*; Type 5 = 'ansa pancreatica', where the duct of Santorini forms an inferior loop and connects with a side branch of the duct of Wirsung

TABLE 4. The distribution of *pancreas divisum* subtypes

<i>Pancreas divisum</i> subtypes	Number of variations	Male, n (%)	Female, n (%)
<i>P. divisum</i> subtype 1	24 (44.4)	8 (40)	16 (47)
<i>P. divisum</i> subtype 2	20 (37)	7 (35)	13 (38.2)
<i>P. divisum</i> subtype 3	10 (18.6)	5 (25)	5 (14.8)
Total	54	20	34

Pancreas divisum were evaluated as; in subtype 1 or classical *divisum*, there was total failure of fusion; in subtype 2, there was only dominant dorsal drainage with the absence of the duct of Wirsung; in subtype 3 or incomplete *divisum*, a small communicating branch was present.

assumed at a P-value of < 0.05. Data documentation and statistical analyses were performed using Excel (v.2007, Microsoft Corporation, Redmond, WA, USA) and SPSS v.14 (SPSS Inc, Chicago, IL, USA).

Results

We retrospectively evaluated the results of 1312 patients who underwent MRCP at our radiology department prior to liver resection surgery or due to suspicion of pancreatobiliary disease. One-hundred fifty four cases were excluded from the study for low MRCP image quality, pancre-

atic head mass making it impossible to analyze the ductal system, and with history of pancreatic surgery. Finally 1158 patients were included in the study, 668 were female (57.69%) and 490 were male (42.31%). The mean age was 60.8 ± 13.4 and the ages were between 16 and 102. The mean age of female patients was 60.5; the mean age of male patients was 61.1.

When we evaluated the course of pancreatic duct, descending type was the most commonly observed (62.5%), and the second most common course type was sigmoid type (30%). The distribution of the pancreatic course types was summarized in Table 2.

The most commonly observed pancreatic duct configuration was Type 3 in 528 patients (45.6%) where 521 patients (45%) had Type 1 configuration. The distribution of the ductal configuration of pancreas is shown in Table 3.

Pancreas divisum was seen in 54 (4.6%) patients. The distribution of *pancreas divisum* subtypes was shown in Table 4. The anatomic variations between the genders are also shown Table 2–4.

There were only two female patients (0.17%) who had pancreatobiliary junction anomaly.

The relationship between Cambridge types and the distribution of the course types, ductal configuration types of main pancreatic duct, *pancreas divisum* subtypes were shown at Table 5.

Besides the anatomical variations of pancreatic duct, we did not observe any *annular pancreas*, pancreatic agenesis, hypoplasia of dorsal pancreas, accessory lobe; we did not demonstrate ectopic pancreas.

Discussion

The pancreas and the pancreatic ductal embryology is moderately complicated, a number of congenital ductal variations have been described such as complete or incomplete *pancreas divisum*, functional *pancreas divisum*, *ansa pancreatica*, *annular pancreas*, anomalous pancreatobiliary junction.^{5,6} We used MRCP to determine the frequency of anatomic variations of the main pancreatic duct and the prevalence of *pancreas divisum* and its subtype.

Our study has the largest sample size in the literature to the best of our knowledge, was to evaluate the frequency of anatomic variations of pancreatic duct by using MRCP during a certain time interval. When we evaluated the course of pancreatic ducts of our study population, descending type was the most common type (62.59%) where sigmoid type

TABLE 5. The relationship between Cambridge classification and the distribution of the course types, ductal configuration types of main pancreatic duct, *pancreas divisum* subtypes

	Cambridge 1; n - (%)	Cambridge 2 and 3; n - (%)	Cambridge 4; n - (%)	Cambridge 5; n - (%)	TOTAL n - (%)
Descending type	612 (85)	82 (11)	25 (3)	5 (1)	724 (62.5)
Sigmoid type	292 (85)	34 (10)	13 (4)	4 (1)	343 (30)
Vertical type	57 (84)	7 (10)	3 (4)	1 (2)	68 (5.5)
Loop type	17 (74)	4 (17)	2 (9)	0 (0)	23 (2)
TOTAL	978 (85)	127 (11)	43 (4)	10 (1)	1158 (100)
Type 1	445 (85)	54(10)	18 (4)	4 (1)	521 (45)
Type 2	34 (81)	6 (14)	2 (5)	0 (0)	42 (3.6)
Type 3	447 (84)	57 (11)	19 (4)	5 (1)	528 (45.6)
Type 4	44 (81)	8 (15)	2 (4)	0 (0)	54 (4.6)
Type 5	8 (62)	2 (15)	2 (15)	1 (8)	13 (1.2)
TOTAL	978 (85)	127 (11)	43 (4)	10 (1)	1158 (100)
PD subtype 1	19 (79)	4 (17)	1 (4)	0 (0)	24 (44.4)
PD subtype 2	16 (80)	3 (15)	1 (5)	0 (0)	20 (37)
PD. subtype 3	9 (90)	1 (10)	0 (0)	0 (0)	10 (18.6)
TOTAL FOR PD	44 (81)	8 (15)	2 (4)	0 (0)	54 (100)

PD = *pancreas divisum*

was the second one as seen in Table 2. In literature, the course of the pancreatic duct varies greatly and the most common one is a descending course with 50%.^{5,14} Itoh *et al.*¹⁴ evaluated pancreatic duct of 77 patients by using multi-slice computed tomography (MSCT) in 2003. Their study population was very small comparing to ours and also they used different imaging modality which was not specific for pancreatic ducts. Shu *et al.*¹⁵ evaluated MRCP investigations of 300 patients, they found that the pancreatic duct courses included descending (66.0%, 192/300), sigmoid (16.0%, 48/300), vertical (10.7%, 32/300), and loop configurations (9.3 %, 28/300) in Chinese population. Gono *et al.*¹⁶ evaluated that 2.2% (11/504) of subjects had loop and reverse-Z type pancreatic course in Japanese. In our study group, descending course was found in about 62.5%, sigmoid course 30% and vertical course 5.5%, loop course 2%, so the prevalence of vertical and sigmoid course were marked different from their value. The different prevalence may be because of ethnicity.

In our study, the most commonly observed pancreatic duct configuration was Type 3 in 528 patients (45.6%) where 521 patients (45%) had Type 1 configuration. These two Wirsung dominant configurations had a rate of 90.6% totally. In literature, the bifid configuration with dominant

duct of Wirsung drainage is most common (60%), a rudimentary, non-draining duct of Santorini (30%), or dominant duct of Santorini without *divisum* (1%) may be present.^{5,6,17} The prevalence rates of types of configuration of the pancreatic ducts are different in our study group and the different prevalence may be because of ethnicity, too. *Ansa pancreatica* is a rare variant where the duct of Santorini takes a curved or looped course before its fusion with the duct of Wirsung. We defined *ansa pancreatica* (Type 5) in 13 patients (1.2%). We could not find an exact prevalence rate of *ansa pancreatica* in literature.

Anomalous pancreaticobiliary ductal junction was found in 2 female patients (0.17%). In this condition, pancreatobiliary reflux occurs into the ducts because of the failure of the sphincter of Oddi.¹⁸ In literature, complications or associated conditions with anomalous pancreaticobiliary ductal junction are choledochal cyst, recurrent cholangitis, bile duct, choledocholithiasis, gallbladder cancer and peritonitis caused by spontaneous perforation.¹⁸ Our two patients had solo anomalous pancreaticobiliary ductal junction, they did not have its complications or associated conditions. We follow up these patients.

During embryonic development, *pancreas divisum* occurs due to the failure of fusion of the ven-

tral and dorsal pancreatic buds. *Pancreas divisum* is a common finding with a reported frequency of 3–13% in autopsy, MRCP and ERCP studies.^{3,6,19-21} In clinical imaging studies using MRCP, *pancreas divisum* was detected in approximately 12% of cases, typically as incidental findings.⁹ Onder *et al.*²² revealed only one patient with *pancreas divisum* among the 590 patients included in the study. Shu *et al.*¹⁵ found the prevalence of the side branch, the Santorini duct and *pancreas divisum* as 4.67% (14/300), 44.3% (133/300) and 7.7% (23/300), respectively in Chinese population. Gonoï *et al.*¹⁶ evaluated that the prevalence of *pancreas divisum* was 2.6 (13/504) in Japanese. We found a prevalence rate of *pancreas divisum* 4.6%. Our study population was mostly from western part of Turkey and our study population was larger than those studies. And we think that the different prevalence may be because of ethnicity, too.

In our study population, female to male ratio was 1.36. When we consider pancreatic duct anatomic variations, we found that female-to-male ratios of Type 2 ($p = 0.03$) configuration and vertical course ($p = 0.0048$) of pancreatic duct were statistically significant. The gender distributions between the other types of configurations of the pancreatic duct were not statistically significant (for Type 1, $p = 0.35$; for Type 3, $p = 0.80$; for Type 4, $p = 0.29$; for Type 5, $p = 0.40$) (Table 3). And also there were not statistically significant differences between the gender for the descending ($p = 0.38$), loop ($p = 0.46$) and sigmoid ($p = 0.49$) course of the pancreatic duct (Table 2). When we analyzed the distributions of subtypes of *pancreas divisum* between the gender, it wasn't any statistically significant difference (for subtype 1, $p = 0.80$; for subtype 2 $p = 0.99$; for subtype 3, $p = 0.49$) (Table 4).

It has been shown that MRCP has been sensitive and specific (85%–100 % for 1.5 Tesla systems) for evaluating pancreatic ductal system.^{1,9,16} The ductal changes of main pancreatic duct are demonstrated on MRCP, however subtle side branch changes can be missed.¹ One of the major limitation of MRCP is the lack of functional information and inability to image the ductal system in distended condition. According to the previous MRCP-based studies, ductal alterations suggesting chronic pancreatitis were reported in approximately 16%.²³ Our study was concordant with the literature; we could only demonstrate dilated side branches of main pancreatic duct in approximately 15% of the cases (Table 5). This can be overcome by using secretin which is known as secretin stimulated MRCP (s-MRCP). Secretin injection during MRCP enhances

the morphology of the main pancreatic duct and side branches and provides information on pancreatic outflow dynamics at the same time.²³⁻²⁵ Secretin is a safe drug and can be administered without any serious side effect. In normal pancreas, the side branches are not visualized after secretin but in patient with early chronic pancreatitis the side branches can show dilatation which is not seen on conventional MRCP.^{1,23-25} Thus s-MRCP has the capability to provide both the structural and functional information.

In our study population, dilatation of pancreatic side branches as a chronic pancreatitis feature was observed in 15% of the patients (Table 5) and 85% of the patients had normal caliber of main pancreatic duct and side branches. When we evaluated the distributions of Cambridge classification between course types and configuration types of the pancreatic duct, only Type 5 configuration (which was *ansa pancreatica*) had statistically different from Type 1, Type 3 configurations ($p = 0.0059$ for Type 1, $P = 0.0129$ for Type 3). The frequency of ductal alterations suggesting chronic pancreatitis was significantly higher in Type 5 configuration by using the Cambridge classification. The Type 4 configuration (which was *pancreas divisum*) and *pancreas divisum* subtypes did not have any statistically significant difference from the others, our study showed no correlation between *pancreas divisum* and ductal alterations suggesting chronic pancreatitis.

There are some limitations of our study. One of them is that we do not have a reference standard such as ERCP or surgery because of ethical issues. Second is the retrospective nature of the study. And third limitation is that most of our patients underwent MRCP at our radiology department with suspected biliary or pancreatic disease, because of that our study population may not sample the whole population.

In conclusion, the results of our study indicated that variants of *pancreas divisum* and normal pancreatic duct variants were not associated with morphologic findings of chronic pancreatitis by using Cambridge classification system. But *ansa pancreatica* might be considered a relevant factor to the onset of chronic pancreatitis. We found that the drainage occurring through the major papilla via the duct of Wirsung had a rate of 90.6% and the prevalence of Type 4 (*pancreas divisum*) and vertical course as 4.6% and 5.5% respectively. The gender distributions of vertical course and Type 2 configurations of pancreatic duct were statistically significant.

References

- Sharma R, Kandasamy D. Imaging in chronic pancreatitis. *Pancreapedia: Exocrine Pancreas Knowledge Base* 2015; DOI 10.3998/panc.2015.26
- Bertin C, Pelletier AL, Vullierme MP. Pancreas divisum is not a cause of pancreatitis by itself but acts as a partner of genetic mutations. *Am J Gastroenterol* 2012; **107**: 311-7.
- Bülow R, Simon P, Thiel R, Thamms P, Messner P, Lerch MM, et al. Anatomic variants of the pancreatic duct and their clinical relevance: an MR-guided study in the general population. *Eur Radiol* 2014; **24**: 3142-9.
- Yu J, Turner MA, Fulcher AS, Halvorsen RA. Congenital anomalies and normal variants of the pancreaticobiliary tract and the pancreas in adults: part 2. Pancreatic duct and pancreas. *Am J Roentgenol* 2006; **187**: 1544-53.
- Turkvatan A, Erden A, Turkoglu M.A, Yener O. Congenital variants and anomalies of the pancreas and pancreatic duct: Imaging by magnetic resonance cholangiopancreatography and multidetector computed tomography. *Korean J Radiol* 2013; **14**: 905-13.
- Mortelé KJ, Rocha TC, Streeter JL, Taylor AJ. Multimodality imaging of pancreatic and biliary congenital anomalies. *RadioGraphics* 2006; **26**: 715-31.
- Conwell DL, Lee LS, Yadav D, Longnecker DS, Miller FH, Mortele KJ, et al. American pancreatic association practice guidelines in chronic pancreatitis-evidence-based report on diagnostic guidelines. *Pancreas* 2014; **43**: 1143-62.
- Adatepe M, Adibelli ZH, Esen OS, Imamoglu C, Yildirim M, Erkan N. Anatomic variations of biliary ducts: magnetic resonance cholangiopancreatography findings of 1041 consecutive patients. *Eur Surg* 2016. DOI 10.1007/s10353-016-0393-5
- Bret PM, Reinhold C, Taourel P, Guilbaud L, Atri M, Barkun AN. Pancreas divisum: evaluation with MR cholangiopancreatography. *Radiology* 1996; **199**: 99-103.
- Uysal F, Obuz F, Uçar A, Seçil M, Iğci E, Dicle O. Anatomic variations of the intrahepatic bile ducts: Analysis of magnetic resonance cholangiopancreatography in 1,011 consecutive patients. *Digestion* 2014; **89**: 194-200.
- Hansen TM, Nilsson M, Gram M, Frøkjær JB. Morphological and functional evaluation of chronic pancreatitis with magnetic resonance imaging. *World J Gastroenterol* 2013; **19**: 7241-6.
- Choueiri NE, Balci NC, Alkaade S, Burton FR. Advanced imaging of chronic pancreatitis. *Curr Gastroenterol Rep* 2010; **12**: 114-20.
- Tirkes T, Sandrasegaran K, Sanyal R, Sherman S, Schmidt M, Cote G, et al. Secretin-enhanced MR cholangiopancreatography: Spectrum of findings. *RadioGraphics* 2013; **33**: 1889-906.
- Itoh S, Ikeda M, Ota T, Satake H, Takai K, Ishigaki T. Assessment of the pancreatic and intrapancreatic bile ducts using 0.5-mm collimation and multiplanar reformatted images in multislice CT. *Eur Radiol* 2003; **13**: 277-85.
- Shu J, Zhang XM, Zeng N. Normal pancreatic duct: evaluation with MR cholangiopancreatography. *Chinese Journal of Medical Imaging Technology* 2006; **4**: 2004-6.
- Gonoi W, Akai H, Hagiwara K, Akahane M, Hayashi N, Maeda E, et al. Meandering main pancreatic duct as a relevant factor to the onset of idiopathic recurrent acute pancreatitis. *PLoS One* 2012; **7**: e37652.
- Alexander LF. Congenital pancreatic anomalies, variants and conditions. *Radiol Clin North Am* 2012; **50**: 487-98.
- Cha SW, Park MS, Kim KW, Byun JH, Yu JS, Kim MJ, et al. Choledochal cyst and anomalous pancreaticobiliary ductal union in adults: radiological spectrum and complications. *J Comput Assist Tomogr* 2008; **32**: 17-22.
- Stimec B, Bulajić M, Korneti V, Milosavljevic T, Krstic R, Ugljesić M. Ductal morphometry of ventral pancreas in pancreas divisum. Comparison between clinical and anatomical results. *Ital J Gastroenterol* 1996; **28**: 76-80.
- Bühler H, Seefeld U, Deyhle P, Largiader F, Ammann R. Clinical significance of pancreas divisum. *Schweiz Med Wochenschr* 1983; **113**: 320-4.
- Adibelli ZH, Adatepe M, Isayeva L, Esen OS, Yildirim M. Pancreas divisum: a risk factor for pancreaticobiliary tumors - an analysis of 1628 MR cholangiography examinations. *Diagn Interv Imaging* 2016; [Epub ahead of print] DOI 10.1016/j.diii.2016.08.004
- Onder H, Ozdemir MS, Tekbas G, Ekici F, Gümüş F, Bilici A. 3-T MRI of the biliary tract variations. *Surg Radiol Anat* 2013; **35**: 161-7.
- Testoni PA, Mariani A, Curioni S, Giussani A, Masci E. Pancreatic ductal abnormalities documented by secretin-enhanced MRCP in asymptomatic subjects with chronic pancreatic hyperenzymemia. *Am J Gastroenterol* 2009; **104**: 1780-6.
- Balci C. MRI assessment of chronic pancreatitis. *Diag Interv Radiol Ank Turk* 2011; **17**: 249-54.
- Balci C, Alkaade S, Magas L, Mamtahan AJ, Burton FR. Suspected chronic pancreatitis with normal MRCP: Findings on MRI in correlation with secretin MRCP. *J Magn Reson Imaging* 2008; **27**: 125-31.