research article

# Comparison between cryoablation and irreversible electroporation of rabbit livers at a location close to the gallbladder

Jianying Zeng[1,2], Zilin Qin[1,2], Liang Zhou[2], Gang Fang[2], Jibing Chen[2], Jialiang Li[2], Lizhi Niu[1,2], Bing Liang[2], Kecheng Xu[2]

[1] School of Medicine, Jinan University, Guangdong Province, Guangzhou, China

[2] Fuda Cancer Hospital, Jinan University School of Medicine, Guangdong Province, Guangzhou, China

Radiol Oncol 2017; 51(1): 40-46.

Received 26 August 2016
Accepted 19 November 2016

Correspondence to: Lizhi Niu, Fuda Cancer Hospital, Jinan University School of Medicine, Guangzhou, China, 510665. E-mail: fudalab@163.com. Bing Liang, Fuda Cancer Hospital, Jinan University School of Medicine, Guangzhou, China, 510665. E-mail: 70404803@qq.com

Conflict of Interest: The authors declare that they have no conflict of interest.

Jianying Zeng and Zilin Qin contributed equally to this work and share the first authorship.

**Background.** The ablation of liver tumors located close to the gallbladder is likely to lead to complications. The aim of this article is to compare the safety and efficacy of irreversible electroporation (IRE) and cryoablation in rabbit livers at a location close to the gallbladder.

**Materials and methods.** We performed cryoablation (n = 12) and IRE (n = 12) of the area of the liver close to the gallbladder in 24 New Zealand white rabbits in order to ensure gallbladder damage. Serum aminotransferase and serum bilirubin levels were measured before and after the ablation. Histopathological examination of the ablation zones in the liver and gallbladder was performed on the 7$^{th}$ day after the ablation.

**Results.** Seven days after the ablation, all 24 animals were alive. Gallbladder perforation did not occur in the IRE group; only mucosal epithelial necrosis and serous layer edema were found in this group. Gallbladder perforation occurred in four rabbits in the cryoablation group. Serum aminotransferase and serum bilirubin levels obviously increased in both groups by Day 3 and decreased gradually thereafter. The elevation in aminotransferase and bilirubin levels was greater in the cryoablation group than the IRE group. Pathological examination revealed complete necrosis of the liver parenchyma from the ablation center to the gallbladder in both groups, but bile duct and granulation tissue hyperplasia were observed in only the IRE group. Full-thickness gallbladder-wall necrosis was seen in the cryoablation group.

**Conclusions.** For ablation of the liver area near the gallbladder, IRE is superior to cryoablation, both in terms of safety (no gallbladder perforation in the IRE group) and efficacy (complete necrosis and rapid recovery in the IRE group).

Key words: cryoablation; irreversible electroporation; liver; gallbladder; ablation

## Introduction

Hepatocellular carcinoma (HCC) is the sixth most prevalent malignancy worldwide[1], and a large proportion of patients with HCC are ineligible for tumor resection due to several factors, such as poor hepatic reserve (cirrhosis), multicentric tumors and extrahepatic disease.[2-3] In HCC patients who are not candidates for surgery or liver transplantation, the National Comprehensive Cancer Network (NCCN) guidelines recommend the use of locoregional ablative methods, such as radiofrequency ablation (RFA), microwave ablation (MWA) and cryoablation. However, when the HCC lesion is located in close proximity to structures such as the major bile duct, gallbladder and diaphragm, ablation should be performed with caution in order to avoid damaging these structures. According to Lee *et al.*, radiofrequency ablation of the area of the liver abutting the gallbladder can cause substantial

complications, including gallbladder perforation, especially when the ablation is performed without maintaining a safe distance.[4] Furthermore, it has been reported that ultrasound-guided percutaneous microwave ablation can be safely used for hepatic malignancies adjacent to the gallbladder, only when the ablation is performed under strict temperature monitoring.[5] Cryoablation is achieved using the high-voltage-dependent release of argon and helium to induce a cycle of low temperature followed by thawing in order to cause physical damage and treat tumors. Because major vessels in close proximity to the tumor can absorb large amounts of heat during ablation (known as the "heat sink effect"), cryoablation can minimize vascular injury during the ablation of liver tumors. In addition, cryoablation is associated with good control, which allows the accurate targeting of the necrotic area and results in few side effects.[8] This method might therefore be suitable for the ablation of liver lesions located near the gallbladder.[6,7] Irreversible electroporation (IRE) is a novel ablation technology that utilizes short pulses of high-voltage electrical energy to induce tissue necrosis. IRE has many special advantages, including short ablation time, preservation of the internal structure of vital organs and lack of the heat/cold-sink effect.[8] Although not yet included in the NCCN guidelines, IRE, owing to its intrinsic characteristics, might be a superior alternative to other ablation techniques for the ablation of tumors situated near the gallbladder. Therefore, IRE was selected for comparison with conventional cryoablation techniques. In this animal experimental study, we performed cryoablation and IRE of the liver area located 0.5 cm from the gallbladder in rabbits, and compared and evaluated the safety and efficacy of these two ablation techniques in order to identify the optimal ablation method for liver tumors located near the gallbladder.

# Materials and methods

## Experimental animals

In total, 24 healthy female New Zealand white rabbits, weighing (2.5 ± 0.2) kg each, were provided by the Animal Experimental Center of Jinan University. They were maintained in a clean, and mechanically-ventilated environment at a constant temperature. The rabbits were randomly assigned to the cryoablation group (n = 12) and IRE group (n = 12). All animals were fasted for 24 h before surgery, and intravenous access was established for intraoperative drug administration. The study was approved by the Research Animal Care and Use Committee of Guangzhou Fuda Cancer Hospital (approval number, LL201402).

## Cryoablation

A cryoablation system (Cryocare™, Endocare, Irvine, CA), composed of the main body, argon/helium gas container and cryoprobes (CRYO-42; Endocare), was used for cryoablation. Rabbits were anesthetized by the intramuscular injection of 44 mg/kg·bw ketamine, intubated and connected to a respirator for mechanically controlled respiration. Intraoperative anesthesia was maintained with 1.5% – 2% isoflurane.

General anesthesia was induced and maintained by the intramuscular injection of 44 mg/kg·bw ketamine. The surgeon had 17 years of experience in cryoablation. The rabbits were fixed in a supine position on the operating table and shaved. The skin was disinfected with iodine, and an abdominal incision was made to expose the liver and gallbladder under sterile conditions. The gallbladder was pressed on the liver, and a cryoprobe with a diameter of 1.4 mm was inserted into the liver until its tip was approximately 0.5 cm away from the gallbladder. The location of the tip was monitored using an ultrasound system (DP-50Vet, Mindray, Shenzhen, China; Figure 1A). When it was confirmed that the cryoprobe was connected to the main equipment, the argon gas was released to freeze the tissue. The cryoablation protocol was a double freeze-thaw cycle consisting of a 2-min freeze and 1-min thaw; this protocol ensured that part of the gallbladder was included within the ablation zone of the ice ball (Figure 1B). No animal died during the cryoablation process. After the cryoablation, the cryoprobe was retrieved. The liver was put back into the abdominal cavity, and conventional abdominal wall sutures were placed to complete the cryoablation. The cryoablation tract was filled in with a thrombin-soaked gelatin sponge and closed with a short suture.

## IRE

General anesthesia was induced with an intramuscular injection of 44 mg/kg·bw ketamine and maintained with 1.5% – 2% isoflurane. Respiration was controlled using a respirator during the operation (tidal volume: 30 ml/time, respiratory rate: 30/min, oxygen concentration: 100%). Before the IRE operation, 0.12 mg/kg·bw pancuronium was

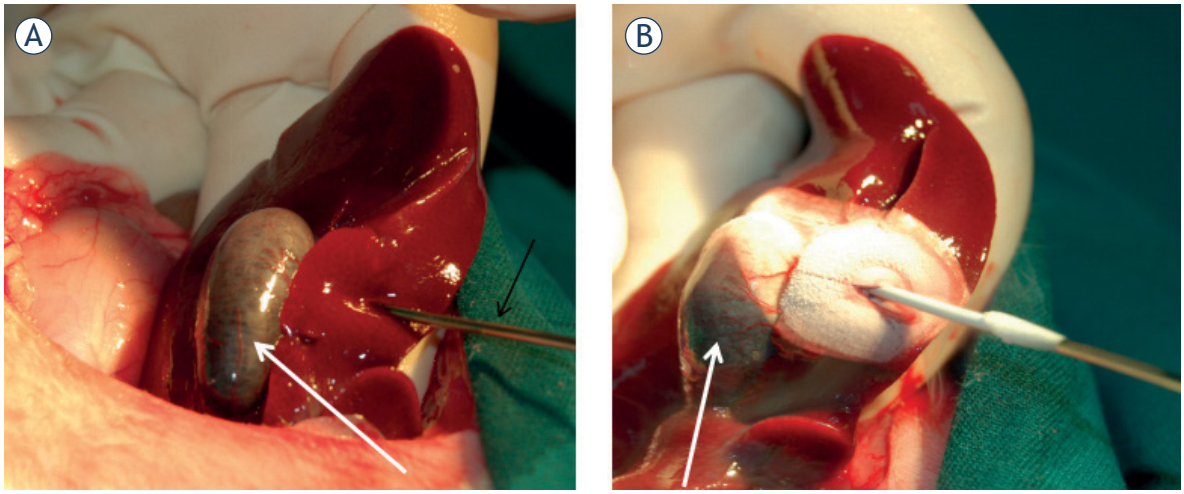


**FIGURE 1.** Photos of the liver and gallbladder before cryoablation. **(A)** Cryoprobe insertion. **(B)** Ice ball formation. The white arrows in **(A and B)** indicate the gallbladder. The black arrow in **(A)** indicates the cryoprobe.

intramuscularly injected to block muscle contraction. IRE was performed using the Angiodynamics Nanoknife system (AngioDynamics, Latham, NY). The Nanoknife system consists of a main body and electrode probes (catalog no. 20400104, AngioDynamics), which were used for electroporation ablation. Monopolar probes were used, which could be changed to achieve 1 – 4 cm of electrode exposure. The size of the ablation zone created depended on the exposed length of the applicator as well as the distance between the probes. When the gallbladder was exposed, two monopolar probes were carefully inserted into the liver (Figure 2A). The probes were inserted to a depth of 0.5 cm into the liver parenchyma under ultrasound guidance (DP-50Vet, Mindray, Shenzhen, China), and were kept 1.5 cm apart and 0.5 cm away from the gallbladder (Figure 3). The monopolar probes were fastened with a spacer device. The ablation parameters consisted of nine groups of ten electrical

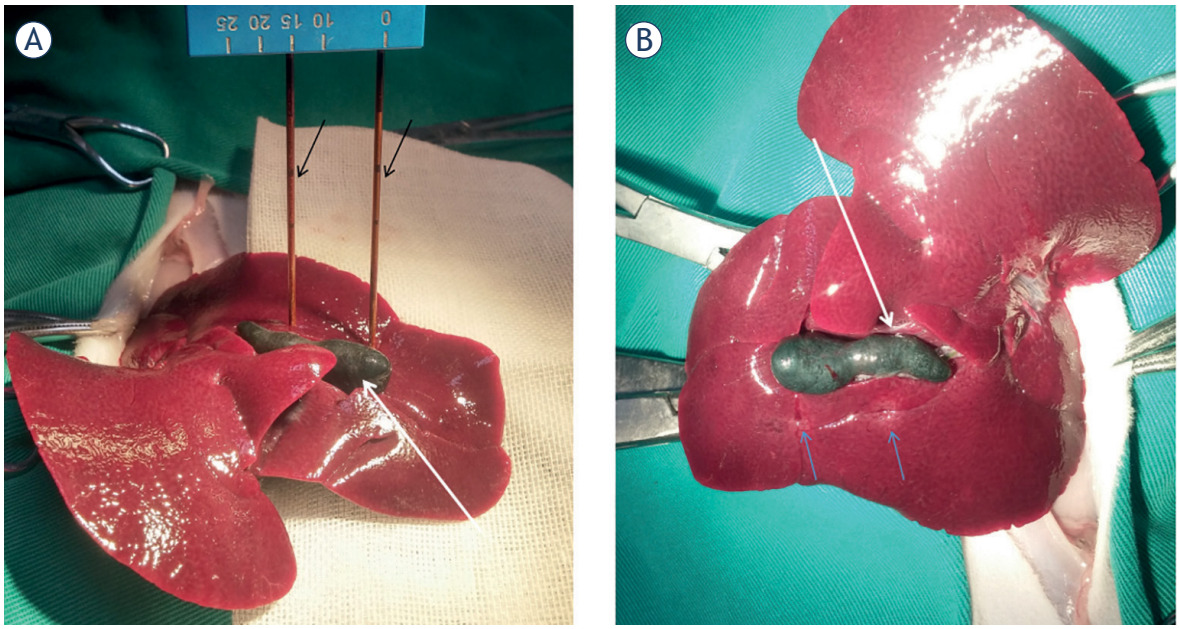


**FIGURE 2.** Photos of the liver and gallbladder before IRE ablation. **(A)** Electrode placement. **(B)** Immediately after the probes are pulled out, the gallbladder and liver do not show any significant changes. The white arrows in **(A and B)** indicate the gallbladder. The black arrows in **(A)** indicate the IRE probes. The blue arrows in **(B)** indicate the insertion sites of the two monopolar IRE probes.

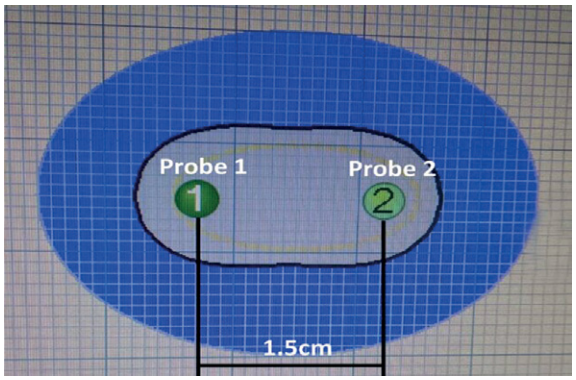


**FIGURE 3.** Distance between two monopolar IRE probes. The two probes are 1.5 cm apart.

pulses (total: 90 pulses), and each electrode pulse was 70-μs long; the output voltage was set at 1500 V/cm. This protocol ensured that the electric field covered part of the gallbladder (Figure 2B). Pulse delivery was synchronized with the R waves of the cardiac cycle in case of arrhythmia. One rabbit died during the IRE ablation because of tracheal intubation failure; we replaced this rabbit with another rabbit. After the IRE ablation, muscle relaxation was reversed with intramuscular injections of 5 μg/kg·bw neostigmine and 5 μg/kg·bw atropine.

### Postprocedure care

The 24 experimental animals returned to consciousness under the monitoring of a senior veterinarian and were sent back to the specific pathogen-free experimental room, which was filled with fresh air and maintained at a constant temperature. All the rabbits were under meticulous care, and pain was managed with intramuscular buprenorphine (0.01 mg/kg) and oral meloxicam (0.4 mg/kg). In addition, the rabbits received daily intramuscular injections of 40 mg/kg·bw cephazolin for 3 days after the surgery in order to prevent infection. For 7 days after the surgery, the animals were observed by veterinarians, who assessed whether the rabbits had suffered any postoperative complications. Feeding was gradually restored over 3 days after the surgery in both groups of animals; however, both food and water intake were lower in the cryoablation group than in the IRE group.

### Detection of serum aminotransferases and serum bilirubin

We collected blood (2 ml, from an ear marginal vein) 1 day before the operation and on days 1, 3, 5 and 7 after the ablation. The blood samples were centrifuged to obtain serum. Hepatic function was measured using an automatic biochemical analyzer (Hitachi-7100; Hitachi, Tokyo, Japan). Alanine aminotransferase/aspartate aminotransferase (ALT/AST) and serum bilirubin levels were determined with kits for in vitro diagnostic use (Biosino Biotechnology and Science Ltd, Beijing, China) by the velocity method.

### Pathology

No animal died after the surgery. At 7 days after the ablation, all the animals were euthanized with an overdose of intravenous pentobarbital sodium (120 mg/kg, Sleepaway; Fort Dodge Animal Health, Fort Dodge, IA). The liver tissues from the ablation tract to the gallbladder were harvested, and the ablation lesions were cut and sectioned from the center. The maximum diameter was measured, and the lesions were photographed. Then, the tissue samples, including the abnormal and adjacent normal tissues, were fixed in 10% neutral buffered formalin, processed routinely for histology, embedded in paraffin, cut into 5-μm-thick slices and stained with hematoxylin and eosin. Pathological analyses were performed by an attending surgical pathologist.

### Statistical analysis

All analyses were performed using GraphPad Prism 5 software (GraphPad Inc., San Diego, CA). The size of the ablation lesions and the serum ALT, AST and bilirubin levels were analyzed using the Student t-test. A P value of $< 0.05$ was considered to indicate a statistical difference, while P values of $< 0.01$ and $< 0.001$ indicated significant differences.

## Results

### Pathological appearance

In the cryoablation group, there were severe inflammatory adhesions between the ablation sites in the liver and gallbladder, the abdominal wall and the mesentery (12/12); the liver ablation zone was khaki-colored and oval. The lesion area had a narrow and sharp edge of light pink edematous tissue, and the ablation range obviously covered the gallbladder. There was a large gray area of necrosis adjacent to the gallbladder, and gallbladder perforation was found in four animals (Figure 4). In the IRE group, there were fewer inflammatory adhesions than in the cryoablation group (5/12 *vs.*12/12).

**TABLE 1.** Sizes of liver and gallbladder lesions at 7 days after the ablation ($\bar{x}$± s)

| Ablation | Major diameter of liver lesions (cm) | | | Gallbladder lesions | |
|---|---|---|---|---|---|
| methods | Gallbladder side (n = 12) | Diaphragm side (n = 12) | P value | Major diameter (cm) | P value |
| Cryo | 1.5 ± 0.4 | 3.8 ± 0.8 | > 0.05 | 1.5 ± 0.4 (n = 8) | > 0.05 |
| IRE | 1.4 ± 0.4 | 4.1 ± 0.7 | > 0.05 | 0.8 ± 0.2 (n = 12) | |

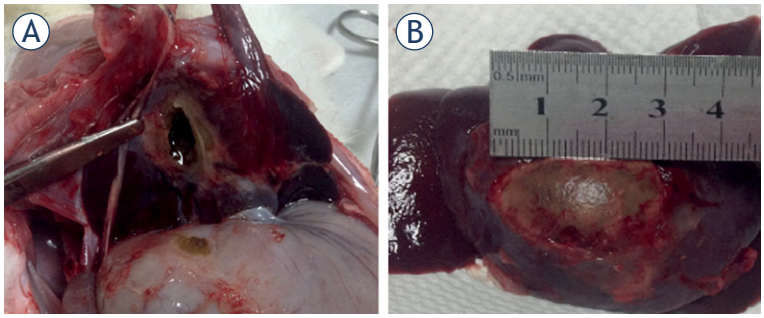


**FIGURE 4.** Photos of the liver and gallbladder after cryoablation. The liver as viewed from the **(A)** gallbladder and **(B)** diaphragmatic side 7 days after the ablation.

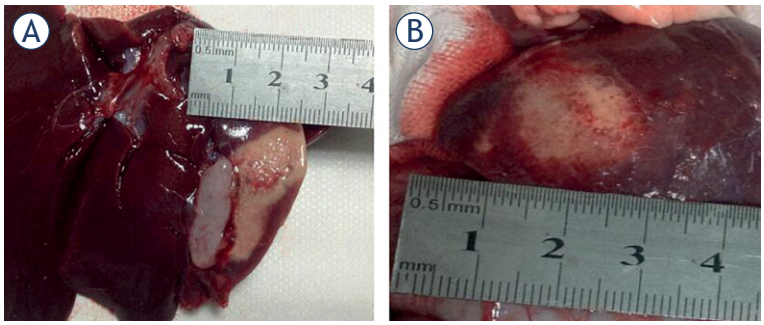


**FIGURE 5.** Photos of the liver and gallbladder after IRE ablation. The liver as viewed from the **(A)** gallbladder and **(B)** diaphragmatic side 7 days after the ablation.

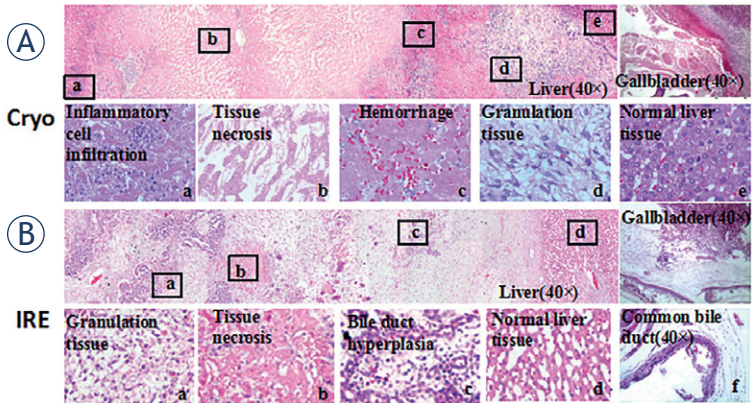


**FIGURE 6.** Pathological changes in the cryoablation (Cryo) and IRE ablation zones 7 days after ablation. **(A)** The top images show the ablated liver and gallbladder areas (magnification, 40×). The bottom images **(A to E)** show enlarged versions of the areas marked in the top images (magnification, 400×). **(B)** The top images and **(F)** show the ablated liver, gallbladder and common bile duct (magnification, 40×). The bottom images **(A to D)** show the enlarged versions of the areas marked in the top images (magnification, 400×).

The lesion area was yellow and oval with sharp edges. The ablated gallbladder tissue appeared grayish-white, but none of the 12 experimental animals showed gallbladder perforation (Figure 5). Details of the sizes of the ablation lesions are presented in Table 1; there were no differences in lesion size between the two groups. As gallbladder perforation was found in four animals in the cryoablation group, we recorded the major diameter of the gallbladder lesions in only eight animals in this group.

There were no intact hepatic cells in the liver slices in both the cryoablation and IRE groups. From the cryoablation tract to the liver edge, the cryolesion appeared as a pink-stained area of disintegrating tissue that included hemorrhagic congestion and tissue necrosis, and it showed nuclear disappearance, no intact cellular structures, a band of local bleeding, and abundant inflammatory cell infiltration (Figure 6A). In the IRE group, the main pathological changes consisted of small bile duct, acute granulation tissue hyperplasia, rare congestion, hemorrhage band and a small amount of inflammatory cell infiltration (Figure 6B). The most conspicuous difference between the two groups was the appearance of the gallbladder: in the cryoablation group, full-thickness gallbladder wall necrosis, muscular collapse and mucosal loss were found, and the necrotic area was large and uniformly stained red. In the IRE group, there was mucosal epithelial necrosis but no full-thickness gallbladder wall necrosis, and serous layer edema were largely concentrated in the area of the gallbladder wall near the liver.

## Changes in serum aminotransferase and serum bilirubin levels

In both groups, the serum aminotransferase and bilirubin levels obviously increased on day 3, gradually decreased thereafter and recovered to normal in a week. At each time point, the serum aminotransferase and serum bilirubin levels were higher in the cryoablation group than in the IRE group (Table 2).

**TABLE 2.** Changes in aminotransferase and serum bilirubin levels over time ($\bar{x}$± s)

| Hepatic function | Ablation method | d-1 | d-1 | d-3 | d-5 | d-7 |
|---|---|---|---|---|---|---|
| ALT (U/L) | IRE | 38.35 ± 3.22 | 167.05 ± 19.50 | 214.83 ± 10.37 | 119.60 ± 12.99 | 68.25 ± 10.08 |
| | Cryo | 39.20 ± 3.90 | 195.03 ± 9.75** | 289.58 ± 12.81** | 142.35 ± 57.85* | 94.90 ± 9.78* |
| AST(U/L) | IRE | 34.10 ± 0.86 | 47.64 ± 0.69 | 60.21 ± 2.55 | 46.78 ± 1.71 | 31.05 ± 0.43 |
| | Cryo | 35.26 ± 2.45 | 60.11 ± 3.44** | 79.12 ± 2.58** | 52.80 ± 3.41* | 37.41 ± 2.50* |
| Serum bilirubin (μmol/L) | IRE | 8.08 ± 2.19 | 26.01 ± 3.68 | 35.15 ± 5.70 | 29.09 ± 3.27 | 21.41 ± 3.39 |
| | Cryo | 7.59 ± 2.01 | 32.72 ± 4.08** | 37.34 ± 6.14* | 35.88 ± 4.28** | 25.86 ± 5.37* |

*P < 0.05 and **P < 0.01, compared with the IRE group

## Discussion

In the study by Fairchild *et al.*, the ice ball extended into the gallbladder lumen (up to a mean distance of 6 mm), but no cases of gallbladder perforation occurred, even when the iceball had extended as far as 1.8 cm into the gallbladder lumen.[9] This may be explained by the theory that the bile within the gallbladdder may dissipate the cooling effect of the cyroprobe around the gallbladder fossa. However, in our study, perforation occurred in one-third of the animals, and inflammatory adhesions occurred in all the animals in the cryoablation group. We attribute this difference to the fact that in our study, the ice ball extended to a far greater distance into the gallbladder lumen, and thus, the cryodamage to the gallbladder was more severe. Furthermore, as more of the gallbladder wall was cryoablated, the "dissipating effect" of the bile was extremely weakened, and a local self-limited inflammatory response resulted in gallbladder wall edema and reactive fluid accumulation, which in turn increased the severity of the gallbladder damage.[9] In contrast, IRE caused a color change in the gallbladder, but no perforation occurred 7 days after ablation. In addition, full-thickness wall necrosis occurred only in the cryoablation group; in the IRE group, the damage to the gallbladder was confined to the mucous layer. This is because IRE is a promising, non-thermal technology that takes advantage of electric fields instead of thermal energy to induce cell death. The most distinctive feature of IRE is that it has little influence on the adjacent large vessels and can preserve the collagen matrix of tissue structures.[10-13] In addition, it does not lead to significant ductal damage if the electrodes are not placed very close to the ducts.[14] In our study, the IRE probes were 0.5 cm away from the gallbladder, and the damage to the gallbladder caused by IRE was acceptable. Thus, our findings indicate that IRE is a potentially safe modality for the ablation of hepatic tumors adjacent to the gallbladder.

Furthermore, although the lesion sizes and changes in the serum aminotransferase and serum bilirubin levels were similar in the two groups, the damage to the liver cells was more severe in the cryoablation group. This phenomenon may be explained as follows: Cryodamage mainly leads to cell necrosis, and secondary injuries can be mediated by the resultant inflammatory reaction.[15] According to current studies, thermal injury may require time to cause gallbladder perforation[16] and perforations are usually found in the acute phase, not the immediate phase.[4] In contrast, electrical injury (IRE) mainly causes cell apoptosis and tissue damage, and repair following IRE is rapid.[8] At 7 days after cryoablation, tissue destruction was still ongoing (areas of cell disruption with hemorrhage), while at the same time point, tissue repair was obvious in the IRE group (areas of bile duct hyperplasia).

Collectively, the above findings indicate that IRE is unlikely to destroy the gallbladder wall and offers the advantage of faster repair of the damaged tissue. Thus, in this study, IRE was found to be superior to cryoablation in terms of protecting the gallbladder, and was a safer procedure than cryoablation.

Complete necrosis of tumor cells with no residual tumor is the main goal of ablation. During cryoablation, ice ball formation can be precisely monitored using ultrasonography or computed tomography. It is impossible to induce tumor cell necrosis in the periphery of the ice ball because the peripheral temperature of the ice ball is 0°C[17], and the temperature that is lethal to cells is at least –20°C.[18,19] To ensure efficacious cryoablation, the edge of the ice ball is usually kept 1 cm beyond the edge of tumor, and the double freeze-thaw cycle protocol is used. In our study, the efficacy of

cryoablation of the liver area near the gallbladder reached the expected levels, as determined based on the appearance (gray-red lesion spread to the gallbladder) as well as histopathological examination (no live cells between the cryoprobe and gallbladder) of the cryozones. IRE ablation has been reported to achieve nearly 100% necrosis in the ablation zone at 24 h in a swine liver model.[8,20] The effectiveness of IRE ablation over a longer time is one of the focuses of this study. Seven days after IRE ablation, not only were the target cells destroyed completely, but the area of bile duct hyperplasia was far greater than the area of pink, disintegrating tissue. All in all, although there was a great difference between the abilities of the two therapies to destroy the liver cells, the long-term effects of both treatments were good.

The major limitation of this article is the lack of short- and long-term studies. Analysis of the pathological appearance of the gallbladder at different time points after ablation would help provide a stronger basis for the clinical application of the two ablation methods. Future experiments should use cholangiography to observe changes in the gallbladder and determine the integrity of the main bile duct.

In conclusion, we compared the safety and efficacy of cryoablation and IRE in rabbit livers, at a location close to the gallbladder. IRE provided complete ablation of the target tissue and completely retained the entire gallbladder structure. In the case of liver tumors situated close to the gallbladder, cryoablation must be performed carefully to avoid direct trauma to the gallbladder. The comparison in this article has a certain meaning in terms of the selection of instruments for liver tumor ablation. However, the clinical value of our findings and long-term curative effect of IRE remain to be confirmed.

## Funding

This study was funded by the Medical and Health Fund of Guangdong Province (2013kw051), China. The funders had no role in study design, data collection and analysis, decision to publish, or preparation of the manuscript.

## Acknowledgements

We would like to thank the native English speaking scientists of Elixigen Company (Huntington Beach, California) for editing our manuscript.

## References

1. Torre LA, Bray F, Siegel RL, Ferlay J, Lortet-Tieulent J, Jemal A. Global cancer statistics, 2012. *CA Cancer J Clin* 2015; **65:** 87-108. DOI: 10.3322/caac.21262.
2. EASL-EORTC clinical practice guidelines: management of hepatocellular carcinoma. *J Hepatol* 2012; **56:** 908-43. DOI: 10.1016/j.ejca.2011.12.021.
3. Grandhi MS, Kim AK, Ronnekleiv-Kelly SM, Kamel IR, Ghasebeh MA, Pawlik TM. Hepatocellular carcinoma: From diagnosis to treatment. *Surg Oncol* 2016; **25:** 74-85. DOI: 10.1016/j.suronc.2016.03.002.
4. Lee J, Rhim H, Jeon YH, Lim HK, Lee WJ, Choi D, et al. Radiofrequency ablation of liver adjacent to body of gallbladder: histopathologic changes of gallbladder wall in a pig model. *AJR Am J Roentgenol* 2008; **190:** 418-25. DOI: 10.2214/ajr.07.2526.
5. Li M, Yu X, Liang P, Dong B, Liu F. Ultrasound-guided percutaneous microwave ablation for hepatic malignancy adjacent to the gallbladder. *Int J Hyperthermia* 2015; **31:** 579-87. DOI: 10.3109/02656736.2015.1014869
6. McGregor HC, Saeed M, Surman A, Ehman EC, Hetts SW, Wilson MW, et al. Gallbladder cryoablation: Proof of concept in a swine model for a percutaneous alternative to cholecystectomy. *Cardiovasc Intervent Radiol* 2016; **39:** 1031-5. DOI: 10.1007/s00270-016-1343-0
7. Kim GM, Won JY, Kim MD, Park SI, Lee do Y, Shin W, et al. Cryoablation of hepatocellular carcinoma with high-risk for percutaneous ablation: Safety and efficacy. *Cardiovasc Intervent Radiol* 2016; **39:** 1447-54. DOI: 10.1007/s00270-016-1384-4
8. Wagstaff PG, Buijs M, van den Bos W, de Bruin D M, Zondervan P J, de la Rosette JJ, et al. Irreversible electroporation: state of the art. *Onco Targets Ther* 2016; **9:** 2437-46. DOI: 10.2147/OTT.S88086
9. Fairchild AH, Tatli S, Dunne RM, Shyn PB, Tuncali K, Silverman SG. Percutaneous cryoablation of hepatic tumors adjacent to the gallbladder: assessment of safety and effectiveness. *J Vasc Interv Radiol* 2014; **25:** 1449-55. DOI: 10.1016/j.jvir.2014.04.023
10. Ben-David E, Ahmed M, Faroja M, Moussa M, Wandel A, Sosna J, et al. Irreversible electroporation: treatment effect is susceptible to local environment and tissue properties. *Radiology* 2013; **269:** 738-47. DOI: 10.1148/radiol.13122590
11. Lee YJ, Lu DS, Osuagwu F, Lassman C. Irreversible electroporation in porcine liver: short- and long-term effect on the hepatic veins and adjacent tissue by CT with pathological correlation. *Invest Radiol* 2012; **47:** 671-75. DOI: 10.1097/RLI.0b013e318274b0df
12. Niessen C, Beyer LP, Pregler B, Dollinger M, Trabold B, Schlitt HJ, et al. Percutaneous ablation of hepatic tumors using irreversible electroporation: A prospective safety and midterm efficacy study in 34 patients. *J Vasc Interv Radiol* 2016; **27:** 480-6. DOI: 10.1016/j.jvir.2015.12.025
13. Kos B, Voigt P, Miklavcic D, Moche M. Careful treatment planning enables safe ablation of liver tumors adjacent to major blood vessels by percutaneous irreversible electroporation (IRE). *Radiol Oncol*. 2015;49(3):234-41. DOI: 10.1515/raon-2015-0031
14. Choi JW, Lu DS, Osuagwu F, Raman S, Lassman C. Assessment of chronological effects of irreversible electroporation on hilar bile ducts in a porcine model. *Cardiovasc Intervent Radiol* 2014; **37:** 224-30. DOI: 10.1007/s00270-013-0731-y
15. Forest V, Peoc'h M, Campos L, Guyotat D, Vergnon JM. Effects of cryotherapy or chemotherapy on apoptosis in a non-small-cell lung cancer xenografted into SCID mice. *Cryobiology* 2005; **50:** 29-37. DOI: 10.1016/j.cryobiol.2004.09.007
16. Livraghi T, Solbiati L, Meloni MF, Gazelle GS, Halpern EF, Goldberg SN. Treatment of focal liver tumors with percutaneous radio-frequency ablation: complications encountered in a multicenter study. *Radiology* 2003; **226:** 441-51. DOI: 10.1148/radiol.2262012198
17. Goel R, Anderson K, Slaton J, Schmidlin F, Vercellotti G, Belcher J, et al. Adjuvant approaches to enhance cryosurgery. *J Biomech Eng* 2009; **131:** 074003. DOI: 10.1115/1.3156804
18. Shurrab M, Wang H, Kubo N. The cooling performance of a cryoprobe: Establishing guidelines for the safety margins in cryosurgery. *Int J Refrig* 2016; **67:** 308-18. DOI: 10.1016/j.ijrefrig.2016.03.007
19. Littrup PJ, Jallad B, Vorugu V, Littrup G, Currier B, George M, et al. Lethal isotherms of cryoablation in a phantom study: effects of heat load, probe size, and number. *J Vasc Interv Radiol* 2009; **20:** 1343-51. DOI: 10.1016/j.jvir.2009.05.038
20. Charpentier KP, Wolf F, Noble L, Winn B, Resnick M, Dupuy DE. Irreversible electroporation of the pancreas in swine: a pilot study. *HPB (Oxford)* 2010; **12:** 348-51. DOI: 10.1111/j.1477-2574.2010.00174.x