

# Various clinical presentations of uveitis associated with durvalumab treatment

Nika Vrabcic, Ana Fakin, Polona Jaki Mekjavic, Urska Janzic, Martina Vrankar, Natasa Vidovic Valentincic

doi: 10.2478/raon-2022-0007

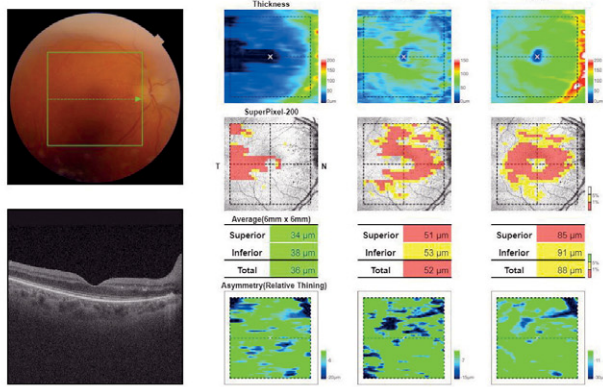
**SUPPLEMENTARY TABLE 1.** Case I. Work up of patient data. Results were within normal limits

Complete blood cell count
C-reactive protein
Erythrocyte sedimentation rate
Serum angiotensin-converting enzyme
Treponemal chemiluminescence immunoassay
Interferon-gamma release assay
Chemiluminescence immunoassay for detection of <i>Borrelia burgdorferi</i>

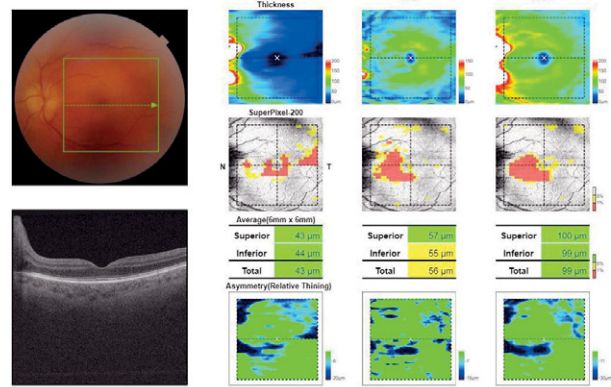
**SUPPLEMENTARY TABLE 2.** Case II. Work up of patient data. All serology and PCR results were negative, except for positive *Toxoplasma gondii* IgG antibodies that indicated past infection

Complete blood cell count
C-reactive protein
Erythrocyte sedimentation rate
Serum angiotensin-converting enzyme
Treponemal chemiluminescence immunoassay
Interferon-gamma release assay
Chemiluminescence immunoassay for detection of <i>Borrelia burgdorferi</i>
Toxoplasma, <i>Toxocara</i> and <i>Bartonella</i> serology testing
SARS CoV-2 antigen testing
Rheumatological autoantibody testing (HEp-2, aCL, anti-beta2GPI, ANCA/MPO/PR3)
Aqueous humour PCR ( <i>Toxoplasma</i> , Varicella zoster virus, Herpes simplex 1, Herpes simplex virus 2)

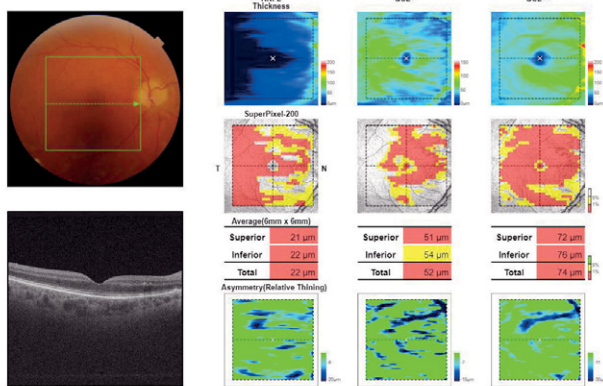
**OD(R) at presentation**



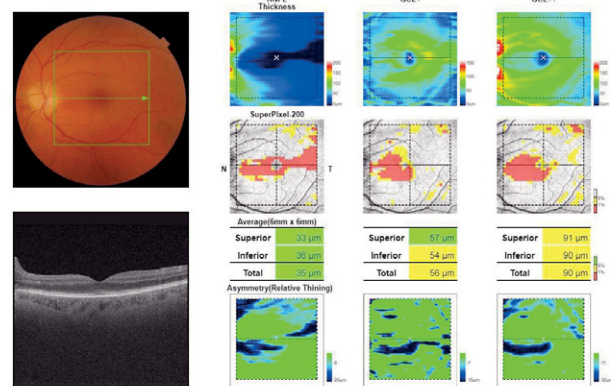
**OS(L) at presentation**



**OD(R) 5-week follow-up**



**OS(L) 5-week follow-up**



**SUPPLEMENTARY FIGURE 1.** Case I. Retinal nerve fibre and ganglion cell layer trend. Right and left eye at presentation and five weeks on methylprednisolone treatment.

OD(R) = oculus dexter (right); OS(L) = oculus sinister (left)