

# Radiomic features as biomarkers of soft tissue paediatric sarcomas: preliminary results of a PET/MR study

Chiara Giraudo<sup>1</sup>, Giulia Fichera<sup>1</sup>, Roberto Stramare<sup>1</sup>, Gianni Bisogno<sup>2</sup>, Raffaella Motta<sup>1</sup>, Laura Evangelista<sup>3</sup>, Diego Cecchin<sup>3</sup>, Pietro Zucchetta<sup>3</sup>

<sup>1</sup> Department of Medicine - DIMED, University of Padova, Padova, Italy

<sup>2</sup> Hematology and Oncology Division, Department of Women's and Children's Health, University of Padova, Padova, Italy

<sup>3</sup> Nuclear Medicine Unit, Department of Medicine - DIMED, University of Padova, Padova, Italy

Radiol Oncol 2022; 56(2): 138-141.

Received 19 November 2021

Accepted 4 March 2022

Correspondence to: Chiara Giraudo, M.D., Ph.D., Department of Medicine - DIMED, Padova University, Via Giustiniani 2, 35100, Padova, Italy.  
E-mail: chiara.giraudo@unipd.it

Disclosure: No potential conflicts of interest were disclosed.

This is an open access article under the CC BY-NC-ND license (<http://creativecommons.org/licenses/by-nc-nd/4.0/>).

**Background.** Pediatric soft tissue sarcomas are rare tumors with rhabdomyosarcoma being the most frequent histotype. Diagnostic imaging plays a significant role in the evaluation of this type of tumors. Thus, aim of this study was to assess the prognostic and diagnostic value of radiomic features extracted from axial T2w images of the primary lesion in children with soft tissue sarcomas examined by PET/MR for staging.

**Methods.** Using an open source software, each lesion was segmented and 33 radiomic features then extracted. Factor and logistic regression analyses were applied to select highly correlating features and evaluate their prognostic role, respectively. Differences in radiomic, demographics, metabolic, and laboratory variables according to tumor grade and histotype were investigated by the Students' and Chi-square tests. In case of differences the diagnostic value of the variable/s was assessed by receiver operating curves.

**Results.** Eighteen children (11 female; mean age  $7.8 \pm 4.6$ -year-old) matched the inclusion criteria. The factor analysis allowed the selection of five highly correlating features which, according to regression analysis, did not influence the outcome ( $p > 0.05$ , each). The feature *lmc1* was significantly higher in low grade lesions ( $p = 0.045$ ) and showed 70.4% accuracy in classifying high grade tumors while the feature variance was significantly lower in rhabdomyosarcomas ( $p = 0.008$ ) and showed 83.3% accuracy for this histotype.

**Conclusions.** In conclusion, our preliminary results suggest that specific radiomic features may act as biomarkers of pediatric soft tissue sarcoma grade and histotype.

Key words: pediatric soft tissue sarcomas; PET/MR; radiomics; oncology

## Introduction

Pediatric soft tissue sarcomas are heterogeneous rare tumors with rhabdomyosarcoma being the most frequent histotype. The recent creation of international working groups allowed the development and implementation of risk-adapted protocols and better supportive care which, overall, increased the survival rates.<sup>1,2</sup> Improvements in this oncological field have been accompanied by tech-

nical developments in diagnostic imaging. In fact, in the last decade, the use of quantitative magnetic resonance (MR) techniques like diffusion weighted imaging (DWI), dynamic contrast enhanced MR imaging (DCE-MRI), and MR spectroscopy as well as the application of complex volumetric histograms analyses, significantly contributed to primary tumours characterization.<sup>3</sup> In adults affected by soft tissue sarcomas, also radiomics demonstrated to provide advanced information about lesions his-

tology and grade.<sup>4,5</sup> As part of the current technical innovations that we can apply in our practice, [18F] fluorodeoxyglucose (FDG) positron emission tomography (PET)/MR (PET/MR) has started to be introduced in the diagnostic work-up of adults and children with soft tissue sarcomas.<sup>6</sup> In fact, this technique not only provides metabolic information with a lower radiation dose than PET/computed tomography (PET/CT) but also allows the simultaneous collection of quantitative MR data.<sup>1</sup> Despite the growing evidence in this diagnostic field, up to now, the role of radiomics features extracted from PET/MR images for pediatric soft tissue sarcomas has not been investigated yet.

The aim of this study was two-fold: i) assess the prognostic value of radiomic features extracted from T2 weighted MR images of the primary tumour of paediatric patients affected by soft tissue sarcomas examined with PET/MR; ii) evaluate if such features may act as biomarkers of tumour grade and histotype.

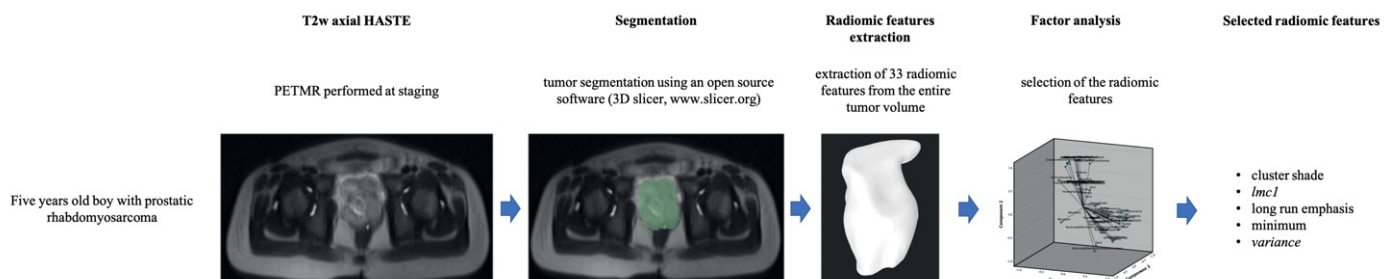
## Patients and methods

Children with histology proven soft tissue sarcomas who underwent PET/MR for staging in our tertiary center from January 2016 to March 2021, including in the protocol a whole-body axial Half-Fourier Acquisition Single-shot Turbo spin Echo imaging sequence (HASTE: Echo Time 95 ms, Repetition Time 1600 ms, and 5 mm slice thickness) were included in this retrospective Institution Review Board approved study. One radiologist with four years of experience in oncological imaging used an open-source software (3D Slicer, [www.slicer.org](http://www.slicer.org)) to segment each primary lesion along tumour margins including the entire volume (Figure 1). The same software was applied to extract 33 radiomic features of first and second order. For each included patient, indices of

metabolic activity simultaneously acquired by PET (*i.e.*, Max and Mean Standardized Uptake Value: SUV<sub>max</sub>, SUV<sub>mean</sub>), demographics (*i.e.*, age and gender), the overall outcome (*i.e.*, alive or deceased at the time of the study), first line laboratory parameters (*i.e.*, hemoglobin (g/L), red blood cells ( $\times 10^{12}\cdot L^{-1}$ ), white blood cells ( $\times 10^9\cdot L^{-1}$ ), platelets count ( $\times 10^9\cdot L^{-1}$ ), lactate dehydrogenase (U/L), and D-dimer (ng/mL)), as well as tumor grade and histotype were collected.

## Statistical analysis

Factor analysis was used to select highly correlating features and logistic regression analysis was applied to determine the prognostic value of the selected radiomic features on the overall outcome. The Student's t-test and the Chi-square test (for continuous and categorical variables, respectively) were used to evaluate if differences in radiomic, demographics, metabolic, and laboratory variables occurred according to tumour grade (subdivided as low and high grade, the former comprising low and intermediate grades without metastatic spread) and histotype (grouped as rhabdomyosarcomas and non-rhabdomyosarcomas). The applied level of significance for all statistical analyses was  $p < 0.05$ . If a statistically significant difference occurred, then the diagnostic value of the variable/s was computed using the receiver operating curves and the results expressed as accuracy, sensitivity, and specificity. To test the reliability of the method, a second radiologist with ten years of experience in musculoskeletal imaging repeated all segmentations and data extraction. Then, for the features selected by the factor analysis, the intraclass correlation coefficient (ICC) was computed using the two-way random effects, consistency, two raters method. Values above 0.750 were considered as excellent.<sup>7</sup> All statistical analyses were performed using SPSS Statistics 25.0 (IBM Corp, Armonk, NY, USA).



**FIGURE 1.** Graphic representation of the development of the proposed radiomic analysis demonstrating the segmentation and extraction of radiomic features from the primary lesion of children affected by soft tissue sarcomas examined for staging by PET/MR and the factor analysis that led to the selection of five highly correlating variables.

TABLE 1. Comparison of demographics, metabolic, and first-line laboratory variables according to tumor histotype and grade

	Histotype <sup>a</sup>		p <sup>a</sup>	Grade <sup>#</sup>		p <sup>a</sup>
	Rhabdomyosarcoma	Non-rhabdomyosarcoma		Low-grade	High grade	
Age (years)	7.2 ± 4.8	9 ± 4.2	0.464	6.1 ± 3.4	9.5 ± 5.2	0.115
Gender (female/male)	7/5	4/2	1.000	7/2	4/5	0.335
SUVmax	5.1 ± 3	5.6 ± 3	0.765	5.3 ± 4	5.3 ± 2	0.998
SUVmean	1.8 ± 1	1.5 ± 1	0.505	1.1 ± 0.3	1 ± 0.2	0.960
Hemoglobin (g/L)	11.4 ± 1.3	11.7 ± 1.4	0.660	11.7 ± 1.6	11.4 ± 1	0.657
Red blood cells count (×10 <sup>12</sup> L <sup>-1</sup> )	4.2 ± 1	4.7 ± 0.5	0.215	4.3 ± 1	4.5 ± 1	0.594
White blood cells count (×10 <sup>9</sup> L <sup>-1</sup> )	5.8 ± 3	5.8 ± 5	0.996	5.7 ± 4	6 ± 3.9	0.889
Platelets (×10 <sup>9</sup> L <sup>-1</sup> )	349 ± 171	386 ± 77	0.636	375 ± 187	351 ± 100	0.748
Lactate dehydrogenase (U/L)	335 ± 86	369 ± 172	0.608	358 ± 131	331 ± 94	0.652
D-dimer (ng/mL)	214 ± 152	2125 ± 3530	0.07	1370 ± 2992	331 ± 297	0.315

<sup>a</sup>rhabdomyosarcoma vs. non-rhabdomyosarcoma; <sup>#</sup>low grade versus high grade lesions; <sup>a</sup>Student's t-test for continuous variables and chi-square test for categorical variables; SUV = standardized uptake value

## Results

Eighteen children (11 female; mean age 7.8 ± 4.6 years old) matched the inclusion criteria and were examined. Twelve (66.6%) children were affected by rhabdomyosarcoma; nine patients had high grade lesions and five showed metastatic spread. Overall, four patients deceased (22.2%).

The factor analysis allowed the selection of five highly correlating features: minimum, lmc1, cluster shade, long run emphasis, and variance (Figure 1). None of the features showed a significant prognostic role on the overall outcome ( $p > 0.05$ , each). The feature lmc1 was significantly higher in low grade soft tissue sarcomas ( $-0.17 \pm 0.05$  vs.  $-0.13 \pm 0.02$ ,  $p = 0.045$ ) and showed 70.4% accuracy in classifying high grade lesions (the value  $-0.14$  demonstrated 77.8% sensitivity and 66.7% specificity). The feature variance was significantly lower in rhabdomyosarcomas ( $23588 \pm 23325$  vs.  $68144 \pm 39009$ ,  $p = 0.008$ ) and showed 83.3% accuracy in classifying this histotype (the value 52314 demonstrated 83% sensitivity and 99% specificity). Each one of the selected radiomic features showed excellent repeatability (minimum = 1.0, 95% CI 0.995–1.000; lmc1 = 0.998, 95% CI 0.996–1.000; cluster shade = 0.999, 95% CI 0.989–1.000; long run emphasis = 0.992, 95% CI 0.879–0.999; variance = 0.998, 95% CI 0.976–1.000).

None of the other variables, including metabolic parameters, showed any statistically significant difference in any of the performed comparisons ( $p > 0.05$ , each) (Table 1).

## Discussion

We presented the first PET/MR-based application of radiomics for paediatric soft tissue sarcoma which demonstrated that the radiomic features lmc1 and variance extracted from a T2w echoplanar fast spin echo sequence can distinguish between paediatric soft tissue sarcomas of different grade and histotype, respectively. Similar results were obtained by Corino *et al.* on adults. In fact, they showed that radiomic features of the first order class extracted from apparent diffusion coefficient (ADC) maps can distinguish between intermediate and high-grade lesions.<sup>4</sup> In our study, we could not use DWI and ADC maps because this sequence was not available for most of our patients. Considering the already demonstrated relationship between ADC and SUV for different tumours including soft tissue sarcomas, further studies are expected to investigate the role of radiomics extracted from DWI.<sup>8</sup>

On the other hand, our results are partially in disagreement with previous evidence in terms of

prognosis.<sup>5,9</sup> Indeed, for instance, Crombé *et al.* showed that radiomic information extracted from DCE-MRI has a significant prognostic role for locally advanced sarcomas.<sup>5</sup> This discrepancy might be due to the different population and to the fact that we did not perform our analyses on contrast enhanced datasets. In fact, usually children referring to our center already underwent a contrast enhanced MR scan of the primary lesion at diagnosis and the PET/MR is done a few days later as part of the whole-body staging (*i.e.*, in addition to unenhanced chest computed tomography) without the need of repeating Gadolinium injection. Regarding tumour grading, as previously suggested by Corino *et al.*, radiomics could be especially beneficial.<sup>4</sup> In fact, the current grading system, considering mitotic rate, degree of necrosis and tumour differentiation, is usually based on core needle biopsies especially on patients who need neoadjuvant chemo-therapy. Thus, it is representative of a selected area and not necessarily of the entire lesion. Given the heterogeneity of soft tissue sarcomas, radiomic biomarkers carry the advantage of a non-invasive, volumetric characterization of the entire primary lesion. Moreover, such imaging-based classifier may serve as replacement in patients that cannot undergo tissue sampling. Last, this complex assessment is also expected to provide new insights on the response to treatment applying, for instance, delta radiomics analyses of information extracted from PET/MR at staging and restaging.

This initial study is affected by several limitations. Firstly, we did not perform any radiomic analysis of the PET dataset because of the well-known challenges associated with PET-based radiomic analysis (*e.g.*, ability to accurately measure heterogeneity features without bias or dependence on volume).<sup>10</sup> Nevertheless, we investigated the role of semiquantitative metabolic variables simultaneously collected from the whole primary lesion by using SUVmax and SUVmean, which did not reveal any statistically significant difference according to tumour histotype and grade. Certainly, further studies including metabolic radiomic analyses and absolute quantitative evaluations are strongly recommended. Moreover, our sample size is limited but soft tissue sarcomas are rare diseases, and our number of patients is in the range of similar studies on children and adults.<sup>4,5</sup> Additionally, the higher prevalence of rhabdomyosarcomas in our sample demonstrates that our population can be considered representative of a larger sample.

In conclusion, specific radiomic features seem to act as biomarkers of pediatric soft tissue sarcomas grade and histotype. Further multicenter studies are expected to confirm this preliminary evidence and assess its role on the diagnostic work-up and therapeutic management of this group of patients.

## References

1. Van Ewijk R, Schoot RA, Sparber-Sauer M, Ter Horst SAJ, Jehanno N, Borgwardt L, et al. European guideline for imaging in paediatric and adolescent rhabdomyosarcoma - joint statement by the European Paediatric Soft Tissue Sarcoma Study Group, the Cooperative Weichteilsarkom Studiengruppe and the Oncology Task Force of the European Society of Paediatric Radiology. *Pediatr Radiol* 2021; **51**: 1940-51. doi: 10.1007/s00247-021-05081-0
2. Ferrari A, van Noesel MM, Brennan B, Zanetti I, Corradini N, Casanova M, et al. Paediatric non-rhabdomyosarcoma soft tissue sarcomas: the prospective NRSTS 2005 study by the European Paediatric Soft Tissue Sarcoma Study Group (EpSSG). *Lancet Child Adolesc Health* 2021; **8**: 546-58. doi: 10.1016/S2352-4642(21)00159-0
3. Orsatti G, Zucchetta P, Varotto A, Crimi F, Weber M, Cecchin D, et al. Volumetric histograms-based analysis of apparent diffusion coefficients and standard uptake values for the assessment of pediatric sarcoma at staging: preliminary results of a PET/MRI study. *Radiol Med* 2021; **126**: 878-85. doi: 10.1007/s11547-021-01340-0
4. Corino V, Montin E, Messina A, Casali PG, Gronchi A, Marchianò A, et al. Radiomic analysis of soft tissues sarcomas can distinguish intermediate from high-grade lesions. *J Magn Reson Imaging* 2018; **47**: 829-40. doi: 10.1002/jmri.25791
5. Crombé A, Fadli D, Buy X, Italiano A, Saut O, Kind M. High-grade soft-tissue sarcomas: Can optimizing dynamic contrast-enhanced MRI postprocessing improve prognostic radiomics models? *J Magn Reson Imaging* 2020; **52**: 282-97. doi: 10.1002/jmri.27040
6. Cassarino G, Evangelista L, Giraudo C, Capizzi A, Carretta G, Zucchetta P, et al. 18F-FDG PET/MRI in adult sarcomas. *Clin Translational Imag* 2020; **8**: 405-12. doi: 10.1007/s40336-020-00395-9
7. Cicchetti DV. Guidelines, criteria, and rules of thumb for evaluating normed and standardized assessment instruments in psychology. *Psychol Assess* 1994; **6**: 284-90. doi: 10.1037/1040-3590.6.4.284
8. Giraudo C, Karanikas G, Weber M, Raderer M, Jaeger U, Simonitsch-Klupp I, et al. Correlation between glycolytic activity on [18F]-FDG-PET and cell density on diffusion-weighted MRI in lymphoma at staging. *J Magn Reson Imaging* 2018; **47**: 1217-26. doi: 10.1002/jmri.25884
9. Spraker MB, Wootton LS, Hippe DS, Ball KC, Peeken JC, Macomber MW, et al. MRI Radiomic features are independently associated with overall survival in soft tissue sarcoma. *Adv Radiat Oncol* 2019; **4**: 413-21. doi: 10.1016/j.adro.2019.02.003
10. Cook GJR, Azad G, Owczarczyk K, Siddique M, Goh V. Challenges and promises of PET radiomics. *Int J Radiat Oncol Biol Phys* 2018; **102**: 1083-89. doi: 10.1016/j.ijrobp.2017.12.268